



Clinical and Histological Evaluation of Socket Grafting Using Different Types of Bone Substitute in Adult Patients

James Rudolph Collins, DDS,* Ely Jiménez, DDS,† Carol Martínez, DDS,† Rubén Tobias Polanco, DDS,‡
Ronaldo Hirata, DDS, MS, PhD,§ Ramy Mousa, MS,|| Paulo G. Coelho, DDS, MS, BS, MSMtE, PhD,¶
Estevam A. Bonfante, DDS, MS, PhD,# and Nick Tovar, PhD**

After the extraction of a tooth, a significant amount of bone loss occurs in the horizontal and vertical dimensions, with the most severe loss found in the horizontal aspect of the alveolar bone.¹⁻⁴ Such bone loss hinders the placement of dental implants and may render immediate placement of dental implants unpredictable. In attempt to assure predictability, clinicians have been developing protocols to ensure the success of an immediately placed implant after tooth extraction.

Recent developments in immediate implant placement protocols include

*Professor and Director of Graduate Periodontics, Department of Periodontics, School of Dentistry, Pontificia Universidad Católica Madre y Maestra (PUCMM), Santo Domingo, Dominican Republic.

†Resident, Department of Periodontology, Graduate School, Catholic University of Santo Domingo, Santo Domingo, Dominican Republic.

‡Professor and Director, Department of Prosthodontics, Graduate School, Catholic University of Santo Domingo, Santo Domingo, Dominican Republic.

§Assistant Professor, Department of Biomaterials and Biomimetics, New York University College of Dentistry, New York, NY.

||Undergraduate Student, New York University College of Dentistry, New York, NY.

¶Associate Professor, Department of Biomaterials and Biomimetics, New York University College of Dentistry, New York, NY; Director, Research Department of Periodontology and Implant Dentistry, New York University College of Dentistry, New York, NY; Affiliated Faculty, Division of Engineering, New York University Abu Dhabi, Abu Dhabi, United Arab Emirates.

#Assistant Professor, Department of Prosthodontics, Bauru College of Dentistry, University of São Paulo, Bauru, SP, Brazil.

**Adjunct Professor, Director, Material Analysis and Testing Laboratory, Department of Biomaterials and Biomimetics, New York University College of Dentistry, New York, NY.

Reprint requests and correspondence to: Estevam A. Bonfante, DDS, MS, PhD, Department of Prosthodontics, Bauru School of Dentistry, University of São Paulo, Alameda Octávio Pinheiro Brisola 9-75, Bauru, São Paulo 17012-901, Brazil, Phone: 55(14) 3235-8904, Fax: 55 (14) 3234-2566, E-mail: estevamab@gmail.com

ISSN 1056-6163/14/02304-489
Implant Dentistry
Volume 23 • Number 4
Copyright © 2014 by Lippincott Williams & Wilkins

DOI: 10.1097/ID.000000000000106

Purpose: This clinical and histological study evaluated the healing of extraction sockets after implantation of a biphasic calcium sulfate (CS) alone or in combination with a gamma-radiated human mineralized allograft.

Materials and Methods: Ten healthy adult patients participated in the study. A minimum of 2 teeth, per patient, extracted for different reasons were evaluated. Each socket was randomly filled to the crest with either (a) a biphasic CS or (b) large particulate gamma-radiated human mineralized allograft in combination with a biphasic CS.

Results: No complications during reentry of the socket site during bone core retrieval, such as inflammation/

immunogenic response, were observed. Histological findings showed a mean new bone (NB) of 33% for sockets filled with biphasic CS and 31% for sockets filled with biphasic CS in combination with allograft material. There was no statistically significant difference in the percentage of NB and the presence of soft tissue between graft materials.

Conclusion: Biphasic CS used alone or in combination with an allograft resulted in the same amount of NB formation in alveolar ridge preservation procedures. (Implant Dent 2014;23:489-495)

Key Words: graft, bone regeneration, socket preservation, clinical

restoration in conjunction with subepithelial connective tissue grafting and bone grafting in the esthetic zone.⁵ In a case series using this protocol, the periimplant tissue response was evaluated, and results suggest that the facial gingival level around single immediately placed implants can be maintained after connective tissue grafting, proper 3-dimensional implant positioning, and placement of bone graft into the implant-socket gap.^{4,5} Although a controversial topic, some clinical and *in vivo* studies have shown that immediate implant placement procedures

after tooth extraction can prevent bone resorption.⁵⁻⁹ Also, a study by Bersani et al¹⁰ suggests that immediate placement may be an alternative for hopeless molars. However, there are a vast number of clinical situations when immediate implant placement into extraction sockets is not recommended.¹¹ They include teeth with acute periapical infection, preexisting periodontal disease, insufficient primary stability, and large dehiscence, especially in the esthetic zone where soft tissue profile becomes critical.¹² When immediate implant placement is not possible,

clinicians should consider the augmentation of the socket extraction.^{13,14}

Studies have shown that bone augmentation procedures with the use of bone graft materials may prevent progressive bone resorption.^{15–18} Autogenous bone graft is considered the gold standard in regenerative procedures because it fulfills the 3 basic requirements for bone regeneration: osteogenesis, osteoinduction, and osteoconduction. Osteogenesis is the mechanism of bone growth from osteoblasts. Osteoinduction involves inducing mesenchymal cells to differentiate into osteoblasts. Osteoconduction is the process that allows bone apposition from existing bone.^{19,20} Despite these 3 essential properties, limitations involving autogenous bone grafting, such as the need for the second surgery, significant donor site morbidity, limitations in quantity, and the potential for complications,^{21,22} have led to the study of alternative materials.

Alternative bone grafting materials include xenografts, allografts, and alloplasts. These biocompatible and readily available materials have been successfully used with membrane barriers for the augmentation of bone after tooth extraction.^{23–27} Xenografts are taken from another species and can cause an immune response. Previous studies have used a bovine xenograft to preserve ridge dimensions with varied success.^{28,29} Allografts are taken from the same species but can potentially transmit disease. They can be processed in various methods as freeze-dried allografts (FDDBA), demineralized allograft (DFDBA) putties, and irradiated cancellous bone. Results may vary depending on allograft type as shown by Piattelli et al,³⁰ in which the differences between FDDBA and DFDBA were studied. FDDBA resorption process is scarce, and cells with acid phosphatase were not found, whereas with DFDBA, the resorption process is present, and cells were positive for acid phosphatase. In FDDBA, the particles furthest from the host bone were lined with newly developed bone, whereas the DFDBA particles were located far from the host bone and composed of scarce extracellular matrix. Alloplasts are synthetic materials manufactured to have

consistent properties, leading to predictable outcomes, and can be manufactured in abundant quantities. One of the first alloplasts used in dentistry was calcium sulfate (CS), which has shown osteoconductive properties.³¹ *In vivo* studies using CS demonstrate alveolar ridge preservation techniques resulting in less contour reduction from the buccal aspect when compared with unassisted socket healing.^{32–35}

Allograft materials can be used in combination with CS to prevent allograft migration into the oral cavity. Toloue et al³⁶ found that CS is as effective as FDDBA in preserving postextraction ridge dimensions in nonmolar extraction sites. The study showed an increase in CS material degradation and new bone (NB) formation after 3 months compared with FDDBA alone in these sites. In an *in vivo* rabbit tibia study, the microvessel density (MVD) was evaluated to determine angiogenic potential using CS versus autogenous bone and concluded that there is a highly significant increase in MVD in defects treated with CS after 4 weeks compared with defects treated with autogenous

bone.³⁷ In a clinical study using CS, histological analysis revealed the complete degradation of CS after 3 months, which was replaced by newly formed bone.^{3,38}

To date, it is still unclear which alveolar ridge preservation technique is the most predictable. The aim of this clinical histological study was to evaluate the effect of the combination of graft materials on NB formation during healing of extraction sockets after a period of 7 to 12 months. A biphasic CS alloplast, alone or in combination with a gamma-radiated human mineralized allograft, was used.

MATERIALS AND METHODS

Ten healthy adult patients (3 men and 7 women, ranging from 18 to 61 years of age) were included in the study. Informed consent was obtained from all patients. Voluntary study candidates reported to the clinical facility at the Graduate School of the Catholic University of Santo Domingo. Potential subjects, who have completed the informed consent process, including

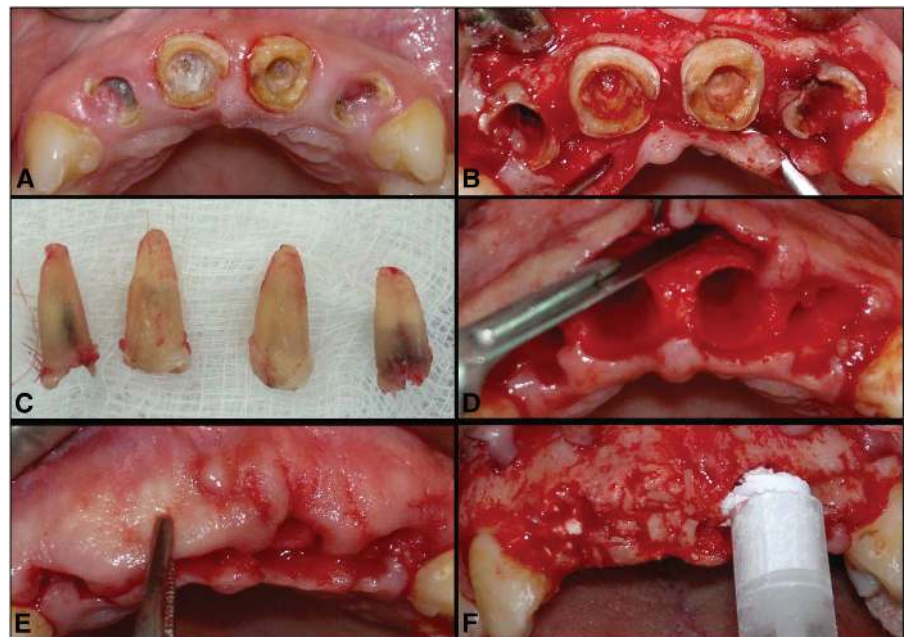


Fig. 1. **A**, Occlusal aspect before extraction, showing extensive decay of incisors. **B**, After mucoperiosteal flap elevation, the buccal wall can be seen. Note the interproximal caries on #7, 8, 9, and 10. **C**, Extracted roots of teeth #7, 8, 9, and 10. **D**, A periosteal relieving incision is made to the base of the buccal flap with a no. 15c blade. **E**, The buccal flap is displaced coronally without tension to evaluate flap margin approximation. **F**, BB graft was injected into the socket of #9 to the level of the crest and on #8, a combination of BB + allograft was used.

the medical history, were screened by the dental examiner to identify those who were eligible for the study. The initial screening procedure consists of a soft tissue assessment before proceeding with study eligibility evaluations.

Initial Examination

Eligible patients were registered for an initial visit. The first 10 patients who completed all the inclusion criteria were invited to participate in the study. Subjects had to be in good general health, without periodontal disease, a minimum of 2 teeth that were anterior to the third molars, and had to be extracted for different reasons, such as extensive caries and root fracture (Fig. 1, A). A radiographic and written refer report indicating the reason for the extraction had to be provided. Qualified subjects were provided with an initial prophylaxis in the Department of Periodontology. All patients were nonsmokers and had no known allergies to the biomaterials used in this study. Before extraction, only scenarios presenting a minimum of 3 socket walls and ≤ 3 mm buccal bone loss were considered.

Surgical Procedure

Ten patients with 2 alveolus each (20 in total) requiring teeth extraction followed by socket grafting for ridge preservation received the treatment. The extraction was carefully performed with local anesthesia in an atraumatic procedure, and when necessary, a resective radicular surgery was indicated in multiradicular teeth to preserve bone (Fig. 1, B–D). Also, depending on the patient needs, a mucoperiosteal flap was elevated. After tooth extraction, the integrity of the 4 walls of the socket and buccal plate measuring ≤ 3 mm from the gingival margin were verified clinically by a North Carolina probe. The extracted teeth included 3 maxillary incisors, 1 mandibular incisor, 2 mandibular canines, 3 maxillary canines, 5 maxillary molars, and 4 mandibular molars. Tissue debris was eliminated from the alveolus, and the bone graft was hydrated after the manufacturer's instructions.

Each of the 20 sockets, 2 per subject, were assigned randomly to one of the 2 treatments: (a) One socket was

filled up to the crest of the alveolus with a synthetic biphasic CS (BondBone [BB]; MIS Implants Technologies, Shlomi, Israel) and (b) One socket was filled with a gamma-radiated human mineralized allograft of large particles (Puros; Zimmer Dental, Tutogen Medical US Inc., Centerpulse, Carlsbad, CA) in combination with BB (1:1). Decorticalization of the bone was made for an increase in blood supply, and soft tissue management was performed to obtain closure of the alveolus. To minimize loss of the FDBA particles, a thin layer of CS was used at the most coronal aspect of the extraction site. Primary closure was obtained with simple sutures. No absorbable collagen wound dressing or barrier membrane was placed (Fig. 1, E and F), and photographs were taken with the patient's approval. Radiographic and clinical follow-up were made at the time of socket preservation at 1-, 3-, 6-, and 12-month time points.

Postoperative Care

All patients received the same written postoperative treatment and indication care: local spray of 0.12% of chlorhexidine 3 times daily for 14 days, amoxicillin and clavulanic acid (875 and 125 mg, respectively) every 12 hours for 7 days. Also, 25 mg of dexametopfen 3 times daily for 3 days was administered as an analgesic. Patients returned after 7 days for a postoperative examination and suture removal and were seen every 2 weeks until soft tissue was closed.

Reentry Procedure

After a minimum of 7 months and maximum of 12 months, patients were administered local anesthesia (2% of lidocaine, DFL, with epinephrine). Crestal and intrasulcular incisions were made to expose bone, and a special trephine (2 × 7 mm) was used to take a core of bone from 9 patients (Fig. 2, A and B). One patient did not return for treatment and could not be contacted. After the samples were retrieved, each patient received 2 endosseous dental implants of various diameter and lengths (Seven Internal Hex; MIS Implants Technologies) (Fig. 2, C and D). The same type of implant surgical procedure was performed for all surgeries under local anesthesia. Full-thickness flaps were elevated, osteotomies made, and implants placed. Sutures were removed after 7 days.

After the bone core was obtained, they were fixed in a 10% of buffered formaldehyde solution and were then referred for histological processing. The bone core samples were then placed in a series of alcohol solution ranging from 70% to 100% for the purpose of dehydration. The samples were infiltrated and finally embedded using a methacrylate-based resin (Technovit 9100; Heraeus Kulzer GmbH, Wehrheim, Germany). The polymerized blocks were then cut into slices (approximately 150 μ m thickness) with a precision diamond saw (Isomet 2000; Buehler Ltd., Lake Bluff, IL), glued to acrylic plates with an acrylate-based

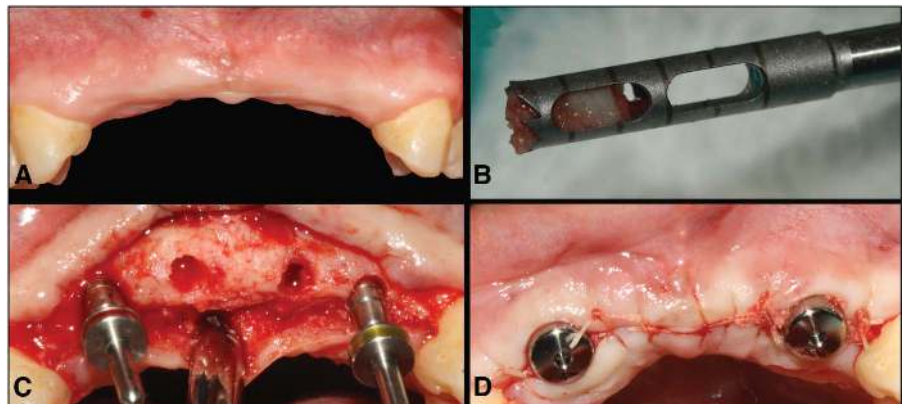


Fig. 2. A, Eleven months after surgery. B, Trephine biopsy removal. C, Implant osteotomies and their parallelism on #7 and 10. C and D, A fixture (13 × 3.75 mm) is placed on #7 and 10 with their respective healing abutments and sutured flap.

cement (Technovit 7210 VLC; Heraeus Kulzer GmbH), and after a 24-hour setting time, ground and polished to a final thickness of approximately 100 μm by means of a series of SiC abrasive papers (280, 400, 800, and 1200 grit) (Buehler Ltd.) using a grinding/polishing machine (Metaserv 3000; Buehler Ltd.) under water irrigation.³⁹⁻⁴¹ A 1- μm polishing compound was used to remove residual scratches. A Stevenel blue and Van Gieson picro fuchsin differential tissue stain (SVG) was used for staining the sections. SVG stains soft tissue green-blue and mineralized tissue red-orange, whereas graft material will stain a brown-black. The stained sections were scanned to digital format using a histology slide scanning system (Aperio Technologies, Vista, CA). Bone, soft tissue, and graft material are then coded using specific colors through Photoshop software (Adobe, San Jose, CA). QWin software (Leica Microsystems Inc., Buffalo Grove, IL) is then used to quantify percentage values based on specified colors with precise results with mega pixel accuracy.

RESULTS

All surgical procedures were uneventful, and there were no complications during the healing period for all patients. Observations showed no signs of infection in either connective tissue or bone in proximity of the surgical sites for all time points. One patient was excluded from the study because he failed to return to the follow-up appointments for unknown reasons. The remaining 9 patients were compliant and during the initial follow-up no complications or infection were observed during reentry surgery for histological sample retrieval.

The histological results for the different groups are presented in Figure 3. From a healing morphology standpoint, a similar healing pattern was observed for both groups, with new vital bone found directly interfacing with the graft materials. Woven bone was observed throughout the bone core, interfacing directly with the allograft material. Blood vessels were observed forming within the allograft material and throughout the bone core. There was slight immunogenic

encapsulation found surrounding bulk amounts of CS. The percent of bone, remaining grafting material, and soft tissue quantified by histomorphometry are presented in Figure 4, A. Histological findings showed no significant differences ($P = 0.7$) in the mean NB: $33 \pm 9\%$ in the BB socket sites and a mean of NB of $31 \pm 19\%$ in the BB +

Puros sites (Fig. 4, B). There were also no significant differences found when comparing the percentage amount of soft tissue ($P = 0.38$) and percentage of graft material ($P = 0.06$) (Fig. 4, C and D). Although not significant, an increased amount of combination of BB and Puros grafting components is found relative to BB alone.




Fig. 3. **A**, Bone core with new vital bone and BB (*) observed in a bluish-greyish color. **B**, Bone core with new vital bone and BB (*) and Puros (+), the latter appearing in a reddish color. Note the similar healing pattern depicted in both micrographs, with new vital bone interfacing the graft materials, and woven bone present throughout the bone core, interfacing directly with the allograft material. Blood vessels can be observed within the allograft material and throughout the bone core. Thin sections were stained with SVG.

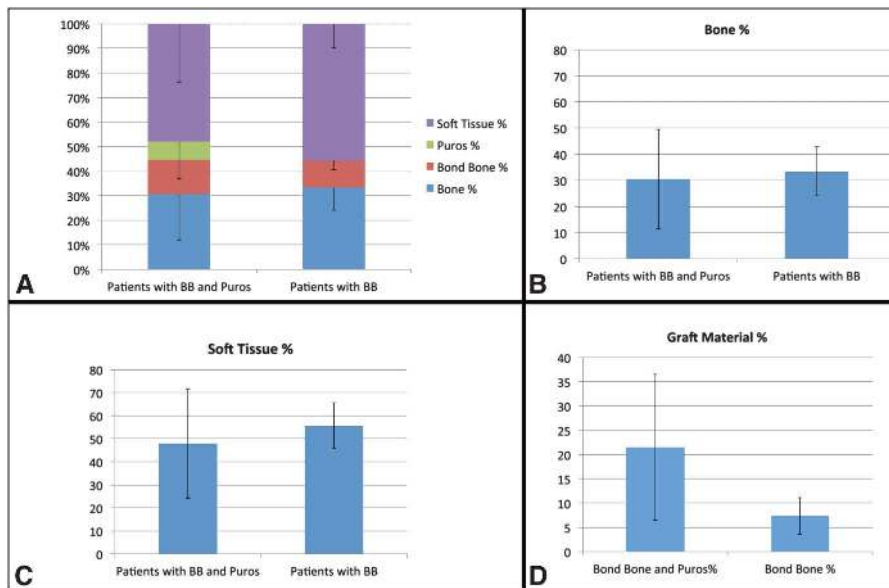


Fig. 4. **A**, Percentage of vital bone, residual graft material (BB or BB + Puros mix), and soft tissue. **B**, Percentage of new vital bone. **C**, Percentage of soft tissue. **D**, Percentage of residual graft particles.

DISCUSSION

This clinical study evaluated the effect of using an alloplast CS bone substitute, BB, alone or in combination with a cortical gamma-radiated human bone mineralized allograft (Puros). The quality and amount of vital NB formation, presence of soft tissue, and residual graft material remaining after socket preservation between 7 and 12 months in paired samples within the same patient were analyzed. Histological findings showed no significant differences in the mean NB between BB socket sites and the combination BB + Puros. In a previous study, 31 extraction sites were selected to determine whether CS is as effective as FDBA in preserving postextraction ridge dimensions and to evaluate the amount of NB formation and remaining graft material after 3 months.³⁶ Histological analysis revealed an average of 32% NB formation in the CS group, which is similar to our findings, $33 \pm 9\%$ in the BB socket. When comparing their 16.7% of NB formation for the FDBA alone, we observed that the BB + Puros mixture within our study gave us a similar NB compared with the BB alone. It is possible that by combining these types of grafts materials, there is an increased amount of NB than just an allograft

material alone. An increased amount of degradation is also observed for the BB alone versus the combination BB and Puros, namely 7% versus 21%, respectively. The combination of graft materials, with their decreased degradation, is evidently maintaining the space within the defect site, preventing the penetration of soft tissue (48%) compared with the BB alone (56%).

The results of our study contradict the study by Guarnieri et al³ who studied the influence of CS hemihydrate on the histopathology pattern of intrasocket regenerated bone and evaluated histologically the effect CS has on the extraction socket sites in 10 patients. Their study found a 58% of newly formed bone and no residual graft after 3 months of histological evaluation of socket preservation with CS, whereas our study found slightly more than 30% of newly formed bone and up to 7% residual graft at greater time points. In another study, Froum et al²⁶ reported the percentage of vital bone formation using bioactive glass and DFDBA of 59.5% and 32.4%, respectively, whereas in the control nongrafted sockets, the amount was 34.7%.

A recent 5-month clinical study by Minichetti et al⁴² used gamma-radiated human mineralized allograft alone after

tooth extraction. Histological analysis of the bone core revealed nonvital spicules of mature calcified bone with a highly organized matrix surrounded by viable noncalcified immature bone matrix or osteoid. Our study showed a similar viable bone matrix in the presence of the allograft.

It has been demonstrated that remnants of CS are completely reabsorbed and replaced by newly formed bone from 3 to 6 months of socket preservation procedure, which is important if implant placement is planned.^{38,43–45} In this study, the BB-treated socket sites showed a small amount of residual material remaining, 7%, whereas the BB + FDBA-treated socket showed a 21% of residual material at postextraction evaluation. This difference in degradation is an important quality to consider when planning the time in which an implant is to be placed. It may be possible to tune the resorption time of graft materials by combining them in varying quantities based on the implant placement treatment plan.

Finally, postsurgical complications associated with exposed membranes have been reported after socket preservation attempts.^{46,47} This study used no membranes and used BB as an initial barrier to prevent soft tissue ingrowth at early healing stages, and no complications were noted.

CONCLUSION

In this human histological study, biphasic CS used alone or in combination with an allograft resulted in the same amount of NB formation in alveolar ridge preservation procedures. CS alone had an increased resorption, which may be an appropriate characteristic if implants are to be placed shortly after the grafting procedure. However, an increased amount of graft material in combination with an allograft, and CS may be needed if implant placement is planned to occur after longer periods after grafting procedure.

DISCLOSURE

The authors claim to have no financial interest, either directly or

indirectly, in the products or information listed in the article.

ACKNOWLEDGMENTS

This study was partially supported by MIS Implants Technologies, Shlomi Israel.

REFERENCES

1. Iasella JM, Greenwell H, Miller RL, et al. Ridge preservation with freeze-dried bone allograft and a collagen membrane compared to extraction alone for implant site development: A clinical and histologic study in humans. *J Periodontol*. 2003;74:990–999.
2. Barone A, Aldini NN, Fini M, et al. Xenograft versus extraction alone for ridge preservation after tooth removal: A clinical and histomorphometric study. *J Periodontol*. 2008;79:1370–1377.
3. Guarnieri R, Pecora G, Fini M, et al. Medical grade calcium sulfate hemihydrate in healing of human extraction sockets: Clinical and histological observations at 3 months. *J Periodontol*. 2004;75:902–908.
4. Van der Weijden F, Dell'Acqua F, Slot DE. Alveolar bone dimensional changes of post-extraction sockets in humans: A systematic review. *J Clin Periodontol*. 2009;36:1048–1058.
5. Tsuda H, Rungcharassaeng K, Kan JY, et al. Peri-implant tissue response following connective tissue and bone grafting in conjunction with immediate single-tooth replacement in the esthetic zone: A case series. *Int J Oral Maxillofac Implants*. 2011;26:427–436.
6. Spinato S, Agnini A, Chiesi M, et al. Comparison between graft and no-graft in an immediate placed and immediate non-functional loaded implant. *Implant Dent*. 2012;21:97–103.
7. Schropp L, Kostopoulos L, Wenzel A. Bone healing following immediate versus delayed placement of titanium implants into extraction sockets: A prospective clinical study. *Int J Oral Maxillofac Implants*. 2003;18:189–199.
8. Watzek G, Haider R, Mensdorff-Pouilly N, et al. Immediate and delayed implantation for complete restoration of the jaw following extraction of all residual teeth: A retrospective study comparing different types of serial immediate implantation. *Int J Oral Maxillofac Implants*. 1995;10:561–567.
9. de Sanctis M, Vignoletti F, Discepoli N, et al. Immediate implants at fresh extraction sockets: An experimental study in the beagle dog comparing four different implant systems. Soft tissue findings. *J Clin Periodontol*. 2010;37:769–776.
10. Bersani E, Coppede AR, de Paula Pinto Prata HH. Immediate loading of implants placed in fresh extraction sockets in the molar area with flapless and graftless procedures: A case series. *Int J Periodontics Restorative Dent*. 2010;30:291–299.
11. Koh RU, Rudek I, Wang HL. Immediate implant placement: Positives and negatives. *Implant Dent*. 2010;19:98–108.
12. Gapski R, Wang HL, Mascarenhas P, et al. Critical review of immediate implant loading. *Clin Oral Implants Res*. 2003;14:515–527.
13. Atalay B, Öncü B, Emes Y, et al. Immediate implant placement without bone grafting: A retrospective study of 110 cases with 5 years of follow-up. *Implant Dent*. 2013;22:360–365.
14. Li J, Wang HL. Common implant-related advanced bone grafting complications: Classification, etiology, and management. *Implant Dent*. 2008;17:389–401.
15. Bernstein S, Cooke J, Fotek P, et al. Vertical bone augmentation: Where are we now? *Implant Dent*. 2006;15:219–228.
16. Kim DM, De Angelis N, Camelo M, et al. Ridge preservation with and without primary wound closure: A case series. *Int J Periodontics Restorative Dent*. 2013;33:71–78.
17. Scheyer ET, Schupbach P, McGuire MK. A histologic and clinical evaluation of ridge preservation following grafting with demineralized bone matrix, cancellous bone chips, and resorbable extracellular matrix membrane. *Int J Periodontics Restorative Dent*. 2012;32:543–552.
18. Brownfield LA, Weltman RL. Ridge preservation with or without an osteoinductive allograft: A clinical, radiographic, micro-computed tomography, and histologic study evaluating dimensional changes and new bone formation of the alveolar ridge. *J Periodontol*. 2012;83:581–589.
19. Rabelo GD, de Paula PM, Rocha FS, et al. Retrospective study of bone grafting procedures before implant placement. *Implant Dent*. 2010;19:342–350.
20. Hoexter DL. Bone regeneration graft materials. *J Oral Implantol*. 2002;28:290–294.
21. Nkenke E, Stelzle F. Clinical outcomes of sinus floor augmentation for implant placement using autogenous bone or bone substitutes: A systematic review. *Clin Oral Implants Res*. 2009;20(suppl 4):124–133.
22. Carlsen A, Gorst-Rasmussen A, Jensen T. Donor site morbidity associated with autogenous bone harvesting from the ascending mandibular ramus. *Implant Dent*. 2013;22:503–506.
23. Araújo PP, Oliveira KP, Montenegro SC, et al. Block allograft for reconstruction of alveolar bone ridge in implantology: A systematic review. *Implant Dent*. 2013;22:304–308.
24. Zitzmann NU, Schärer P, Marinello CP, et al. Alveolar ridge augmentation with Bio-Oss: A histologic study in humans. *Int J Periodontics Restorative Dent*. 2001;21:288–295.
25. Becker W, Clokie C, Sennerby L, et al. Histologic findings after implantation and evaluation of different grafting materials and titanium micro screws into extraction sockets: Case reports. *J Periodontol*. 1998;69:414–421.
26. Froum S, Cho SC, Rosenberg E, et al. Histological comparison of healing extraction sockets implanted with bioactive glass or demineralized freeze-dried bone allograft: A pilot study. *J Periodontol*. 2002;73:94–102.
27. Smukler H, Landi L, Setayesh R. Histomorphometric evaluation of extraction sockets and deficient alveolar ridges treated with allograft and barrier membrane: A pilot study. *Int J Oral Maxillofac Implants*. 1999;14:407–416.
28. Araújo M, Linder E, Wennström J, et al. The influence of Bio-Oss collagen on healing of an extraction socket: An experimental study in the dog. *Int J Periodontics Restorative Dent*. 2008;28:123–135.
29. Fickl S, Zuhr O, Wachtel H, et al. Dimensional changes of the alveolar ridge contour after different socket preservation techniques. *J Clin Periodontol*. 2008;35:906–913.
30. Piattelli A, Scarano A, Corigliano M, et al. Comparison of bone regeneration with the use of mineralized and demineralized freeze-dried bone allografts: A histological and histochemical study in man. *Biomaterials*. 1996;17:1127–1131.
31. Thomas MV, Puleo DA. Calcium sulfate: Properties and clinical applications. *J Biomed Mater Res B Appl Biomater*. 2009;88:597–610.
32. Sbordone L, Bortolaia C, Perrotti V, et al. Clinical and histologic analysis of calcium sulfate in treatment of a post-extraction defect: A case report. *Implant Dent*. 2005;14:82–87.
33. Calhoun NR, Neiders ME, Greene GW Jr. Effects of plaster-of-paris implants in surgical defects of mandibular alveolar processes of dogs. *J Oral Surg*. 1967;25:122–128.
34. Frame JW. Porous calcium sulphate dihydrate as a biodegradable implant in bone. *J Dent*. 1975;3:177–187.
35. Scarano A, Orsini G, Pecora G, et al. Peri-implant bone regeneration with calcium sulfate: A light and transmission electron microscopy case report. *Implant Dent*. 2007;16:195–203.
36. Toloue SM, Chesnoiu-Matei I, Blanchard SB. A clinical and histomorphometric study of calcium sulfate compared

with freeze-dried bone allograft for alveolar ridge preservation. *J Periodontol.* 2012;83:847–855.

37. Strocchi R, Orsini G, Iezzi G, et al. Bone regeneration with calcium sulfate: Evidence for increased angiogenesis in rabbits. *J Oral Implantol.* 2002;28:273–278.

38. Guarnieri R, Aldini NN, Pecora G, et al. Medial-grade calcium sulfate hemihydrate (surgiplaster) in healing of a human extraction socket: Histologic observation at 3 months: A case report. *Int J Oral Maxillofac Implants.* 2005;20:636–641.

39. Marin C, Granato R, Suzuki M, et al. Biomechanical and histomorphometric analysis of etched and non-etched resorbable blasting media processed implant surfaces: An experimental study

in dogs. *J Mech Behav Biomed Mater.* 2010;3:382–391.

40. Giro G, Tovar N, Witek L, et al. Osseointegration assessment of chairside argon-based nonthermal plasma-treated Ca-P coated dental implants. *J Biomed Mater Res A.* 2013;101:98–103.

41. Witek L, Marin C, Granato R, et al. Characterization and in vivo evaluation of laser sintered dental endosseous implants in dogs. *J Biomed Mater Res B Appl Biomater.* 2012;100:1566–1573.

42. Minichetti JC, D'Amore JC, Hong AY, et al. Human histologic analysis of mineralized bone allograft (Puros) placement before implant surgery. *J Oral Implantol.* 2004;30:74–82.

43. Thalmair T, Fickl S, Schneider D, et al. Dimensional alterations of extraction sites after different alveolar ridge preserva-

tion techniques—A volumetric study. *J Clin Periodontol.* 2013;40:721–727.

44. Artzi Z, Tal H, Dayan D. Porous bovine bone mineral in healing of human extraction sockets. Part 1: Histomorphometric evaluations at 9 months. *J Periodontol.* 2000;71:1015–1023.

45. De Leonardis D, Pecora GE. Prospective study on the augmentation of the maxillary sinus with calcium sulfate: Histological results. *J Periodontol.* 2000;71:940–947.

46. Araújo MG, Lindhe J. Dimensional ridge alterations following tooth extraction. An experimental study in the dog. *J Clin Periodontol.* 2005;32:212–218.

47. Araújo MG, Lindhe J. Ridge preservation with the use of Bio-Oss collagen: A 6-month study in the dog. *Clin Oral Implants Res.* 2009;20:433–440.