COLUMBIA | COLLEGE OF DENTAL MEDICINE

CLINICAL CASE

Surgical Techniques Using Bone Cement

Live Surgery Cases Review (Extraction and Socket Management)

James B. Fine, DMD

Nicolas Elian, DDS

ABCA™ AUGMA BONE CEMENT ACADEMY

AUGMA BONE CEMENT ACADEMY

Case 1

Tooth #3, Upper Right Molar

Tooth #3, Upper Right Molar

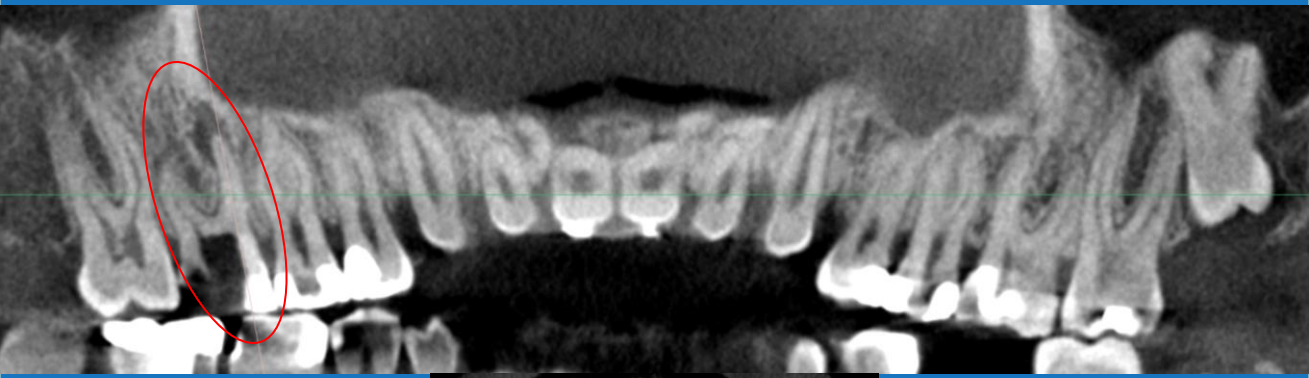

Tooth #3, Upper Right Molar

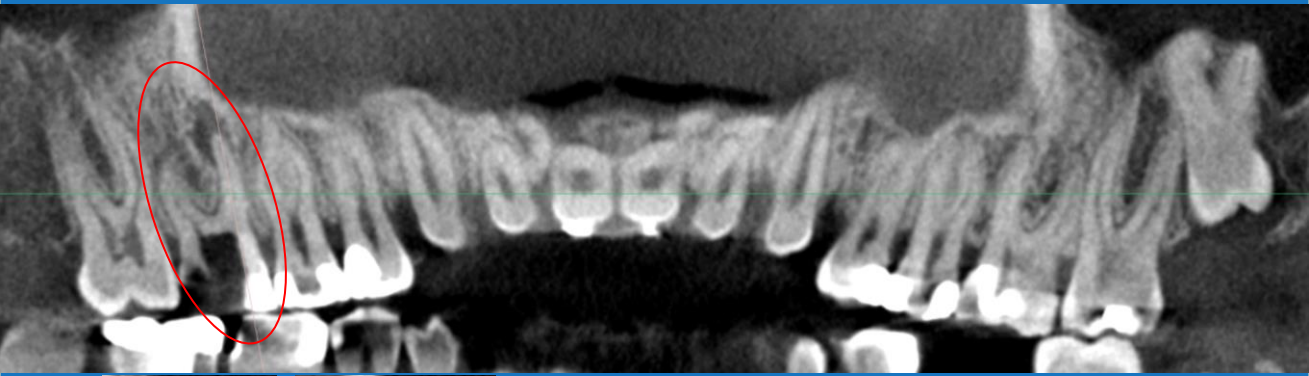

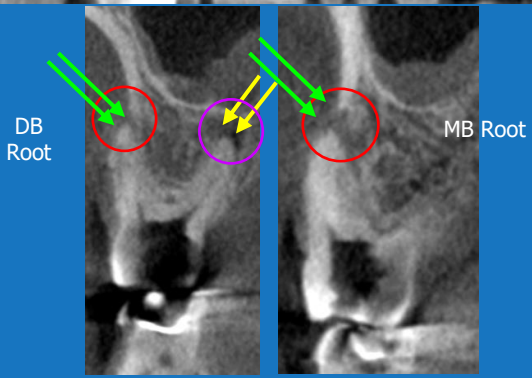

- *Mesio Buccal Root: Periapical Lesion and Fenestration*
- *Disto Buccal Root: Fenestration*
- *Palatal Root: Periapical Infection*

Tooth #3, Upper Right Molar

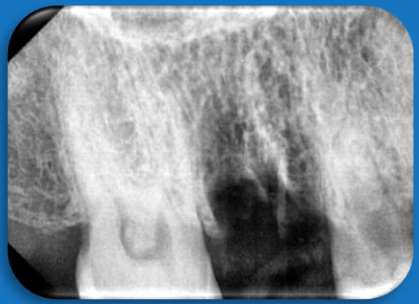

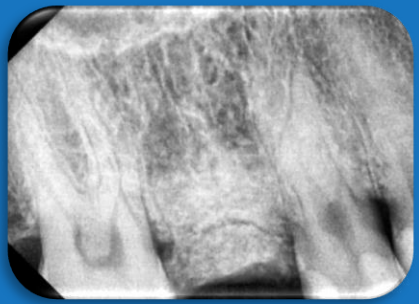

Post-Op with Bone Cement

Tooth #3, Upper Right Molar

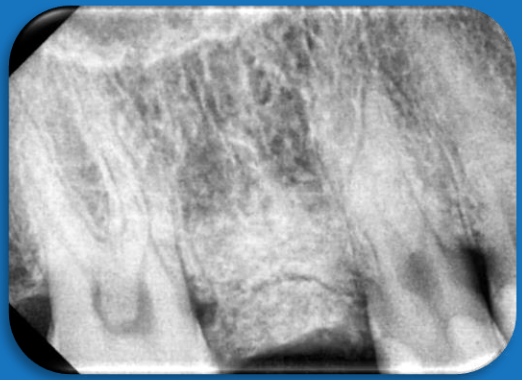

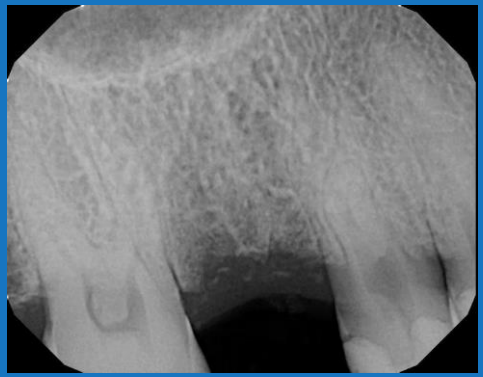

3 & 1/2 Month Follow Up with Bone Cement

Tooth #3, Upper Right Molar

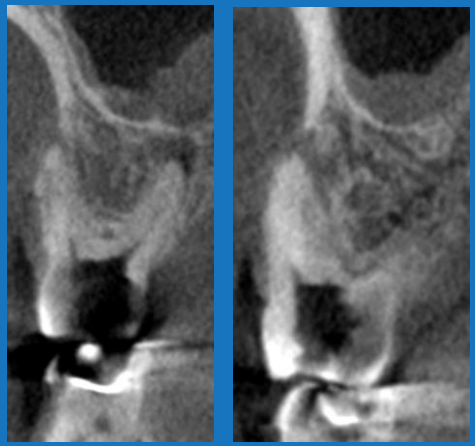

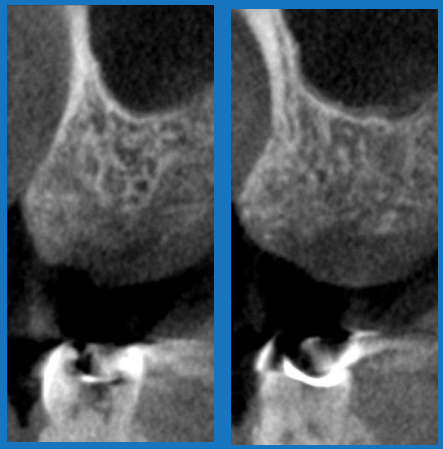

3 & 1/2 Month Follow Up with Bone Cement

Case 2

Tooth #28, Lower Right Premolar

Tooth #28, Lower Right Premolar

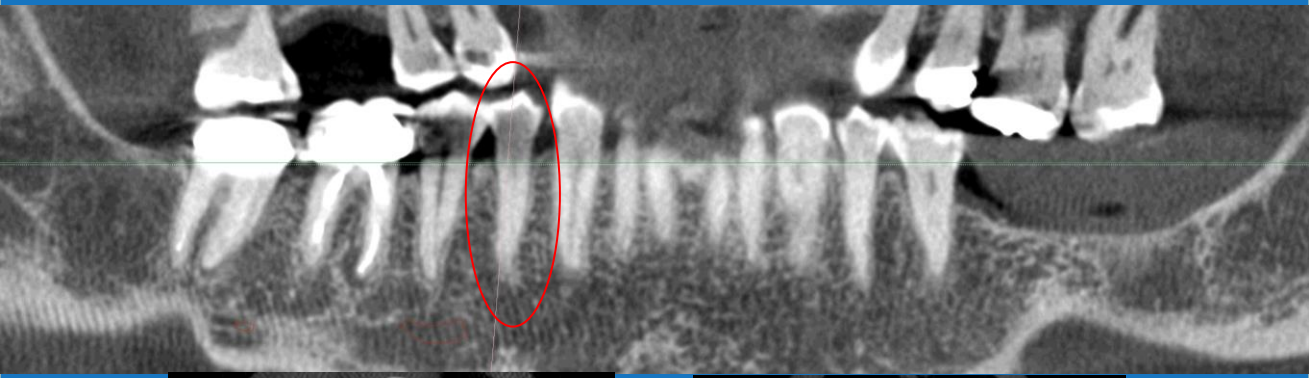

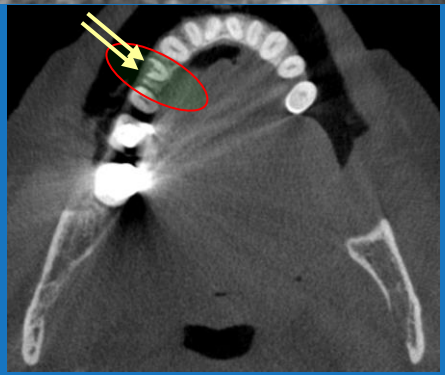

Tooth #28, Lower Right Premolar

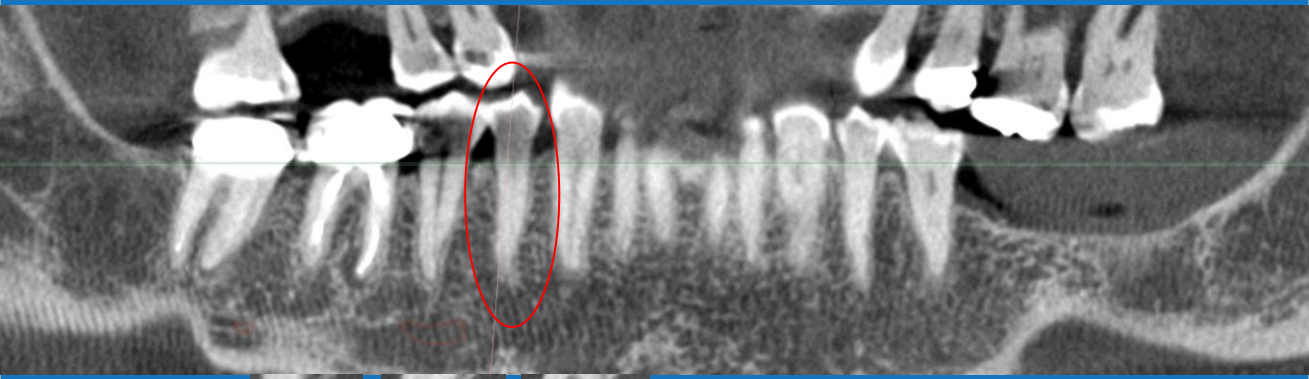

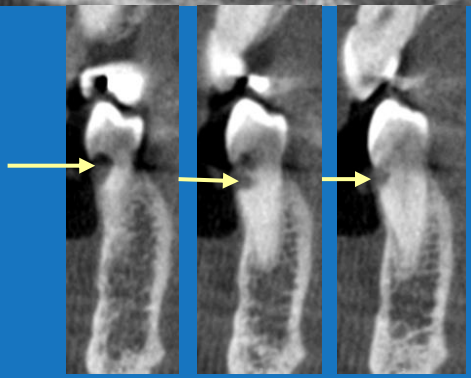

- *External Root Resorption*
- *Thin Buccal Plate*

Tooth #28, Lower Right Premolar

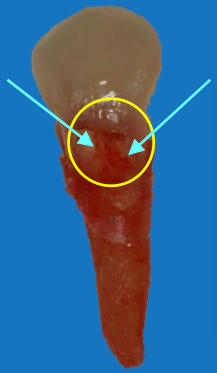

Post-Op with Bone Cement

Tooth #28, Lower Right Premolar

3 & 1/2 Month Follow Up with Bone Cement

Tooth #28, Lower Right Premolar

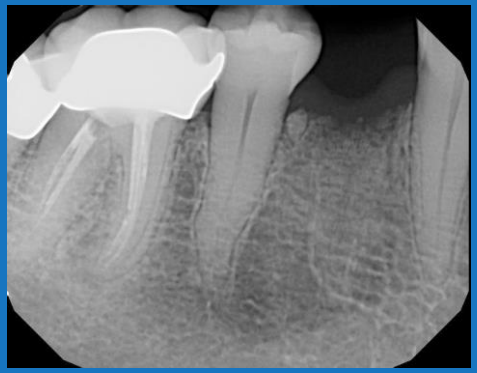

3 & 1/2 Month Follow Up with Bone Cement

Tooth #28, Lower Right Premolar

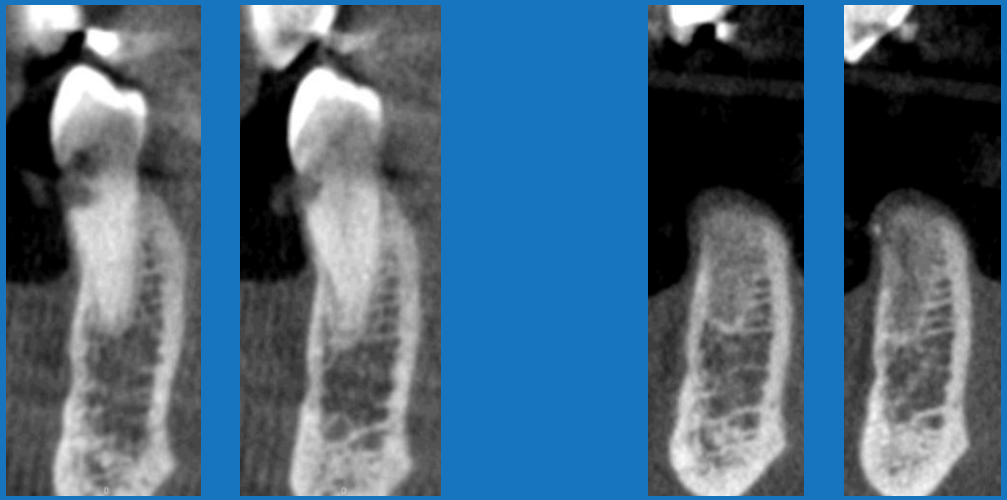

3 & 1/2 Month Follow Up with Bone Cement

Tooth #28, Lower Right Premolar

3 & 1/2 Month Follow Up with Bone Cement

ABCA™
ALCYMA BONE CEMENT ACADEMY

Thank You