



OPEN ACCESS

Published: October 31, 2023

**Citation:** Ferreira, J. C. and Kurtzman, G. M., 2023. Minimal invasive horizontal ridge augmentation with Calcium Sulfate bone cement: A case series. *Medical Research Archives*, [online] 11(10).

<https://doi.org/10.18103/mra.v11i10.4598>

**Copyright:** © 2023 European Society of Medicine. This is an open-access article distributed under the terms of the Creative Commons Attribution License, which permits unrestricted use, distribution, and reproduction in any medium, provided the original author and source are credited.

DOI:

<https://doi.org/10.18103/mra.v11i10.4598>

ISSN: 2375-1924

## RESEARCH ARTICLE

# Minimal invasive horizontal ridge augmentation with Calcium Sulfate bone cement: A case series

Jose Camelo Ferreira<sup>1</sup> and Gregori M. Kurtzman<sup>2\*</sup>

<sup>1</sup>Private practice, Algarve. Portugal

<sup>2</sup>Private practice, Silver Spring, Maryland, USA.

\*[drimplants@aol.com](mailto:drimplants@aol.com)

## ABSTRACT

**Background:** The objective of this retrospective study is to assess the minimal invasive technique for augmenting horizontal ridge or bone defects using biphasic calcium sulfate with hydroxyapatite bone cement.

**Methods:** This study focused on 14 partially edentulous patients: 5 males and 9 females, aged between 36 and 82 years old. These patients were non-smokers and had no chronic diseases or received radiation treatment in the last 6 months. During their initial consultation, all patients underwent cone beam computed tomography. Horizontal bone augmentation was necessary for all patients to facilitate prosthetically driven implant surgery. Bond Apatite bone cement horizontal grafting was used for all patients, along with immediate or delayed implants (with or without immediate loading). One year after the final prosthetic placement, all cases were evaluated. The clinical progression of peri-implant volume and tissue quality was documented photographically, along with exams conducted every 6 months. The complete follow-up timeline for these cases ranged from 1 to 5 years.

**Results:** A total of 34 implants were placed in the grafted zones, distributed among 14 patients. None of the patients reported any abnormal discomfort or swelling after surgery, and there were no infections or significant post-surgery complications noted. One year after the placement of various fixed prosthetic rehabilitations, all 100% of the implants remained stable with healthy peri-implant soft tissue and very satisfactory aesthetic results.

**Conclusion:** The Bond Apatite bone cement has demonstrated exceptional effectiveness in reconstructing or augmenting horizontal defects and narrow ridges, increasing the available bone/soft tissue volume and soft enabling successful placement of implants, whether immediate or delayed, with or without immediate loading. Furthermore, the use of Bond Apatite resulted in minimal post-operative complications and an impressively low rate of postoperative infections, allowing for minimally invasive augmentation surgery, eliminating the need for extensive surgical flaps and free tension flap sutures typically associated with this type of procedure.

**Keywords:** Bond Apatite, horizontal augmentation, dental implants, ridge augmentation, minimally invasive surgery, soft tissue enhancement, Calcium sulphate.

## Introduction

One of the modern objectives across all surgical techniques in various medical fields is to minimize patient complications, reduce duration of surgery, prevent surgical accidents, and mitigate postoperative issues while maintaining or even improving predictability and outcomes. Consequently, minimally invasive surgery has become the standard of care for many procedures and has gained widespread acceptance in almost all medical specialties. This principle holds true for oral surgical reconstruction, including Horizontal Bone Augmentation (HBA), as traditional approaches often involve traumatic surgeries with prolonged recovery periods and associated expenses. Such procedures can lead to various postoperative complications, such as soft tissue dehiscence, infections, neurosensory disturbances, graft integration failures, implant failures, pain, trismus, hematoma, and postoperative hemorrhage<sup>1-3</sup>.

Numerous techniques and materials have been employed in HBA surgeries. Those include but are not limited to the use of barrier membranes for Guided Bone Regeneration (GBR), particulate grafting materials, onlay block grafting techniques, distraction osteogenesis, ridge split techniques, the application of autologous blood concentrates (PRP, PRF) to stimulate bone formation rates, and in some cases, a combination of these techniques in staged approaches<sup>4</sup>.

Calcium sulfate, a synthetic material, has been utilized for decades in orthopedics, plastic surgery, oncologic, and maxillofacial surgeries to address osseous deficiencies resulting from trauma or inflammation. Numerous studies have highlighted its advantages as a bone

graft material<sup>5</sup>. Dreesman was the first to document the use of calcium sulfate (CS) as a regenerative material in the late 1800's<sup>6</sup>. In 1955, Lilo and Peltier<sup>7</sup> employed CS cylinders to repair bone defects in dogs, concluding that it stimulated bone growth when covered by the periosteum.

Contemporary research has further substantiated the value of CS as a versatile grafting material with a multitude of beneficial properties, including biocompatibility, osteoconductivity, angiogenic potential, homeostasis support, non-toxicity, bacteriostatic qualities, affordability, and an effective barrier effect decreasing the need for an overlaying membrane<sup>8</sup>. Payne and Cobb<sup>9</sup> demonstrated the superior migratory capacity of gingival fibroblasts in CS compared to other barrier materials, suggesting its suitability for second-intention healing scenarios. CS as a grafting material is also recognized for its effectiveness, predictability, practicality, cost-effectiveness, and ease of handling in various aspects of implant surgery<sup>10</sup>. Some studies have emphasized CS as an excellent transport medium for growth factors, small molecules, and medications (including antibiotics), in addition to being a rich source of calcium ions<sup>8</sup>.

However, biphasic calcium sulfate (BCS) alone has limitations as a short-term space maintainer for small defects<sup>5</sup>. Nevertheless, the Bond Apatite® (Augma Biomaterials, Spotswoods, NJ) a composite graft formulation, consisting of a mixture of BCS and 33% hydroxyapatite granules of varying sizes, enables successful larger bone reconstruction, including horizontal augmentations, through minimally invasive techniques<sup>5</sup>. This is achieved without the need

for membranes, autogenous bone harvesting, fixation pins/screws, tension-free flaps, or periosteal releasing incisions. As a result, it reduces invasiveness in terms of the affected surgical area, duration of the surgery, flap size, surgical and post-operative bleeding, surgical complications, and postoperative inflammation or infection<sup>8,11,12</sup>. Another significant feature of BA is its phased reabsorption. The CS component initially resorbs, while the slower resorption rate of hydroxyapatite particles maintains the deficit space for an extended period. This prevents undesirable ingrowth of soft tissue into the defect, allowing time for vascularization and new bone formation<sup>13</sup>. Furthermore, BCS/HA can be a preferred material for socket preservation, often yielding similar or even superior results compared to bovine-derived xenografts<sup>14</sup>. Histological examination of samples taken at 3 months after graft placement revealed the presence of new bone in close proximity to the residual scaffold particles of Bond Apatite, which at that time comprised only 10% of the grafted site. An analysis at 8 months showed that the sample components consisted of 79% bone, 11% bone marrow, 7% connective tissue, and a mere 3% residual graft particles<sup>11</sup>.

The study presented here is a collection of 14 different cases in which Bond Apatite was used as the sole graft material for horizontal bone augmentation (HBA) and soft tissue enhancement utilizing minimally invasive techniques. The objective was to assess the efficacy of BA bone cement as a graft material for horizontal augmentation, whether in aesthetic or non-aesthetic zones, with or without immediate implant placement.

## Study objectives:

The objective of this retrospective study is to assess the minimal invasive horizontal ridge augmentation technique in various types and sizes of defects. This evaluation will involve the use of biphasic calcium sulfate with hydroxyapatite bone cement (BA). Simultaneously, the study aims to substantiate, from a clinical and objective perspective, the numerous advantages and attributes associated with the utilization of this material as a bone graft.

## Methods and materials:

The inclusion criteria for this study were participants aged 21 or older with good oral hygiene. Those individuals had lost one, multiple, or all of the teeth on the arch, resulting in a reduction of horizontal volume (both bone and soft tissue) in either the maxilla or mandible. Exclusion criteria included individuals who were smokers, participants with uncontrolled diabetes, those who had undergone radiotherapy or immunotherapy treatments within the previous 6 months.

The materials used in the study included Augma Bond Apatite<sup>®</sup> bone cement, 3DBond<sup>™</sup> Biphasic calcium sulfate cement (Augma Biomaterials) that was used in only one case. Either simultaneous with graft placement or following a delayed healing approach implants would be placed (Nobel Biocare, Active or Parallel), along with associated abutments and prosthetic rehabilitations. Ora Aid<sup>™</sup> (TBM Corp., Seoul, South Korea) or Augma Shield<sup>™</sup> (Augma Biomaterials) wound dressing was applied over the surgical site when immediate loading was not performed.

## Clinical cases:

This study focused on 14 patients, comprising 5 males and 9 females, all of whom required horizontal bone augmentation for implant placement related to insufficient ridge or alveolar bone volume resulting from various pathologies. A standardized evaluation process was employed for all patients, consisting of an intraoral examination, cone beam computed tomography (CBCT) scan, orthopantomography, and intraoral scanning. This information was then imported into the DTX Studio implant diagnosis software (Envista Holdings Corporation, Brea, CA) for comprehensive assessment of both bone and soft tissue, with a focus on achieving the ideal positioning for future crown/implant rehabilitation. Subsequently, surgical plans were developed based on the specific needs of each case.

All surgical procedures were conducted under local anesthesia using 4% Articaine with 1:200,000 epinephrine. Following case evaluation and digital surgical planning, the patients were categorized into three different groups:

1. Horizontal bone grafting without immediate implant(s) placement.
2. Horizontal bone grafting with immediate implant(s) placement.
3. Horizontal bone grafting with immediate implant placement and immediate loading, including temporary prosthodontics (four patients).

Each of the 14 cases was assigned a numerical identifier from 1 to 14 to facilitate reference and evaluation. Consistent surgical principles and techniques were applied to all 14 patients throughout the study. Those included:

**SURGICAL FLAP:** A minimal full thickness surgical flap was created with no vertical releasing incisions, or in some cases, a minimal singular mesial or distal vertical release incision, ensuring it did not extend more than 2 or 3 mm beyond the mucogingival line to prevent connecting the flap to muscle movements. The flap was detached from the bone only about 1 or 2 mm ahead of the bony defect, and the periosteum was left intact.

**PREPARATION OF THE BONE DEFECT:** All granulation tissue and any remaining soft tissue on the bones surface to be grafted were meticulously removed. In all mandibular cases and some maxillary cases, extensive decorticalization of the bone was performed using a tungsten round bur in a handpiece.

**BONE CEMENT APPLICATION:** The BA cement (Augma Bond Apatite) syringe was activated, and the bone cement was promptly placed into the site of the defect to be grafted. It was then shaped and dried by pressing dry gauze with the fingers for 3 to 4 seconds, followed by an additional 3 to 4 seconds with a dry gauze and a large-tip periosteal elevator. Following this, the bone cement was left undisturbed to harden (set), and any residue over the soft tissues was carefully removed using "shaving-like" motions.

**MEMBRANES AND FIXATION PINS:** No membranes or fixation pins were utilized in any of the cases. The BA served as both the graft material and a self-contained barrier.

**SOFT TISSUE GRAFTING:** No soft tissue grafting was performed in any of the 14 cases to assess the effect of BA on the healing and proliferation of soft tissues.

**SUTURE:** In all cases, surgical flaps were maintained under tension during closure and sutured without any periosteal releases. In some instances, the cement was left exposed by 1 to 2 mm (maximal closure) at the crest. A 4.0 Teflon suture was used in most cases, while a 4.0 Supramid nylon suture (S Jackson Inc., Alexandria, VA) was employed in a few of the cases. For all cases, except those with immediate temporary crown placement, a wound dressing (Augma Shield™) was applied and sutured over the closed flap to safeguard the exposed bone cement from potential leakage during the initial healing phase until there was adequate soft tissue proliferation over the graft.

**TEMPORARY REHABILITATION:** None of the 14 patients wore removable prostheses over

the grafted site for a minimum of 2 months. In all groups, one patient did not receive any temporary rehabilitation for 2 months, while others used their existing fixed prostheses, and some were provided with new fixed pre-made temporary prostheses, adapted with temporary titanium abutments after implant placement.

#### FIRST GROUP: HORIZONTAL BONE GRAFTING WITHOUT IMMEDIATE IMPLANT(S) PLACEMENT

Was comprised 2 cases of peri-implantitis with total loss of osseointegration of the prior implant present. Case 1: Located in the region of the 1st right maxillary molar (Fig 1). Case 2: Located in the region of the 1st left mandibular molar (Fig 2).

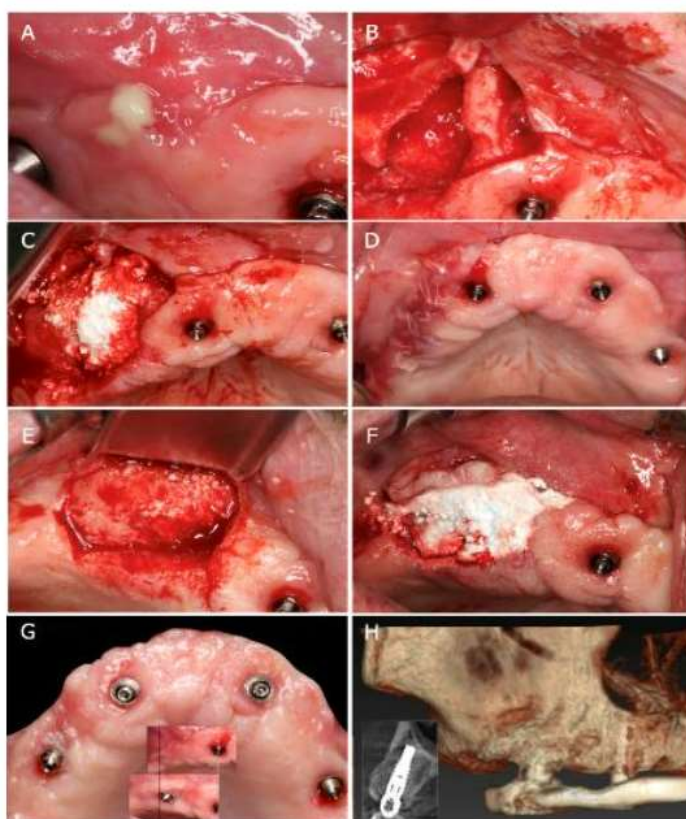


Figure 1- Maxilla 1<sup>st</sup> right molar. A- initial presentation following hybrid removal, B- bone defect following explantation, C- BA application, D- suture placement and Augma Shield application, E- site flap exposure 6-months later, F- implant placement and new layer of BA applied, G- final aspect and soft tissue volume comparison, and H- CBCT demonstrating bone surrounding the new implant after osseointegration.

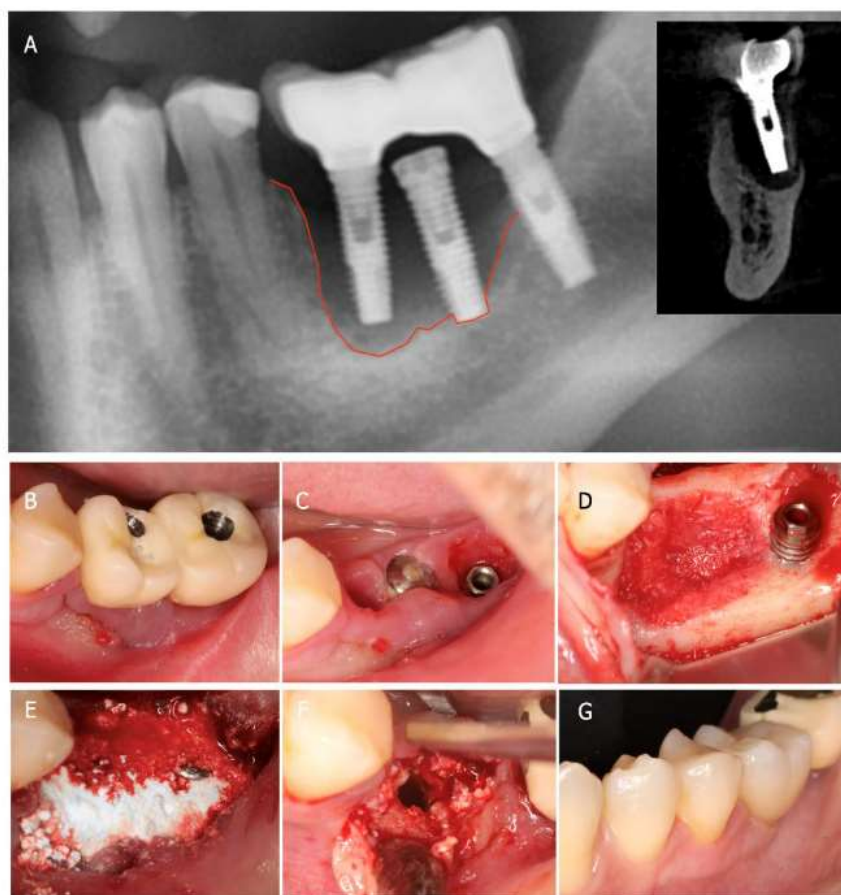


Figure 2- Mandible 1<sup>st</sup> left molar. A- initial radiograph demonstrating bone loss around the implants, B- clinical presentation of the current prosthetics and surrounding soft tissue, C- removal of the infected implants, D- bony defect resulting, E- BA placement into the bony defect, F- implant placement, and G- new prosthetics placed on the new implants.

Both cases involved implants that were removed along with their prostheses due to complete absence of surrounding bone, with support solely from granulation tissue and the prosthesis itself. These cases exhibited a high degree of suppuration. After a 6-week waiting period allowing healing of the explantation site, a small flap was created with minimal mesial surgical release (limited to the mucogingival line). Careful removal of all granulation tissue was performed at the site, followed by the application of Bond Apatite (BA) to cover the bony defect. In the mandible, intense decorticalization was conducted before bone graft placement. The application of BA followed the same

procedure as in all 14 cases of this study as outlined under methods and materials. Subsequently, the bone cement was left undisturbed, and closure was achieved using a 4.0 Teflon suture while keeping the flap under tension.

After a further 6-month healing period, a second surgery occurred for implant placement in the same location as the previous failed implants. An insertion torque of 45 Ncm was achieved, and healing abutments were placed. Following a 6-month integration period, the restorative phase was completed with a final Procera crown placed in the mandibular case. The maxillary case was

restored with the old All-on-4 hybrid prosthesis that was adapted to the new implant due to financial considerations.

Another case (case 3) in this group involved horizontal augmentation of the left mandible at the premolars and 1st molar. A crestal minimally invasive flap was created with only a small vertical releasing incision positioned one tooth ahead of the bony defect. Following robust decorticalization, 3D Bond™ biphasic calcium sulfate (BCS) bone cement (Augma Biomaterials) was placed, and the flap was sutured under tension. The use of 3D Bond BCS aimed to encourage surface vascularization of the bony defect. After a 5-week healing period, the same small flap was reopened, and BA cement was applied without repeating the decorticalization step due to observed substantial cortical surface bleeding. After an additional 6-month healing

period, a new flap was created without any vertical release incisions. In this procedure, one poorly positioned premolar was extracted, and three implants were placed into the grafted area. Another application of BA was performed to augment the horizontal bone volume around the implants and enhance the volume and quality of the soft tissue. The flap was closed in the same manner as before. Six months later, a new small crestal flap was made over the three implants to expose them and allow for the placement of healing abutments. A new layer of bone cement was applied over the implants with healing abutments. A single suture was used between the implants to keep the flap open while restricting excessive movement (Fig. 3). Final impressions were taken after 2-weeks, and the final restoration a three unit Procera bridge was placed 1.5 months later.

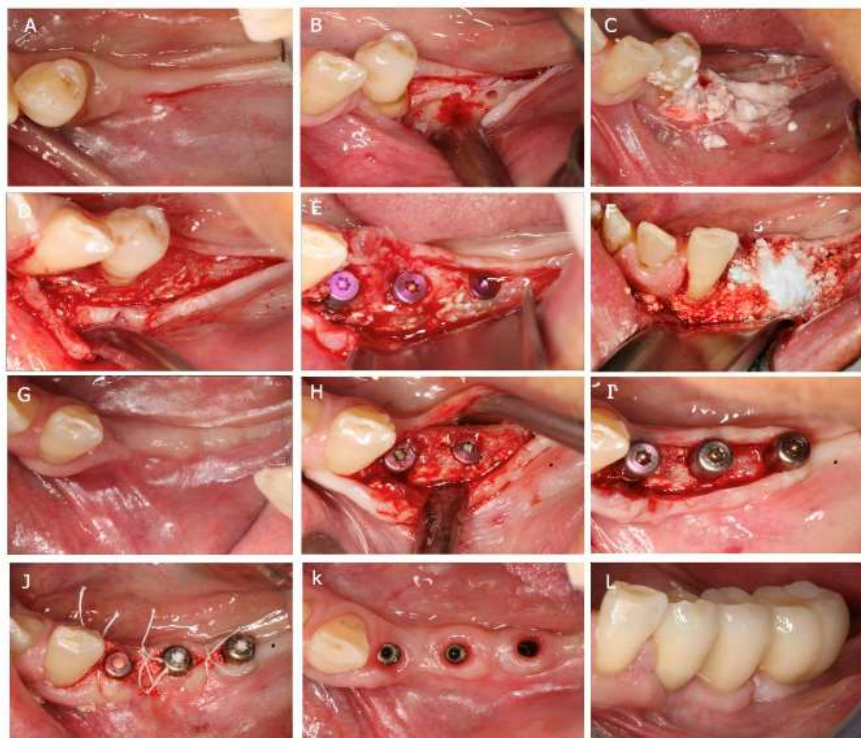


Figure 3- Mandible lateral augmentation with 3D Bond and Bond Apatite. A- initial presentation, B- 1<sup>st</sup> flap, C- 3D Bond placement, D- 6-months post BA placement, E- implant placement, F- BA layer over the newly placed implants, G- 6-months post implant placement, H- implant exposure, I- healing abutments placed, J- suture placement after BA placement, K- gingival presentation showing lack of inflammation prior to placing the final prosthesis, and L- final prosthesis placed.

The last 2 cases of this 1st group are total maxillary horizontal augmentation and bilateral sinus augmentation in preparation for an All-on-X approach (cases 4 and 5).

In case #4, the patient retained the right canine and the 2nd right molar as retention for the partial denture they would be utilizing during healing before the restorative phase could be performed. The surgery involved elevating two separate surgical flaps with a very small central mesial vertical releasing incision confined to the keratinized tissue. The right-side surgery, including sinus augmentation and horizontal bone augmentation, and the right flap was sutured under tension. No periosteal releasing

incisions were made. Subsequently, the left quadrant was treated similarly to the right side. The patient chose not to use any rehabilitation for 2 months due to her confinement at home during the Covid-19 pandemic. After 2-months, a new removable prosthesis was created, featuring only palate support. After an additional 4-months, six implants were placed using guided surgery, the two remaining teeth were extracted, and the new removable prosthesis was adapted to serve as a temporary hybrid prosthesis. Following another 6-months, a final Nobel Procera hybrid prosthesis was fabricated and placed (Fig. 4).

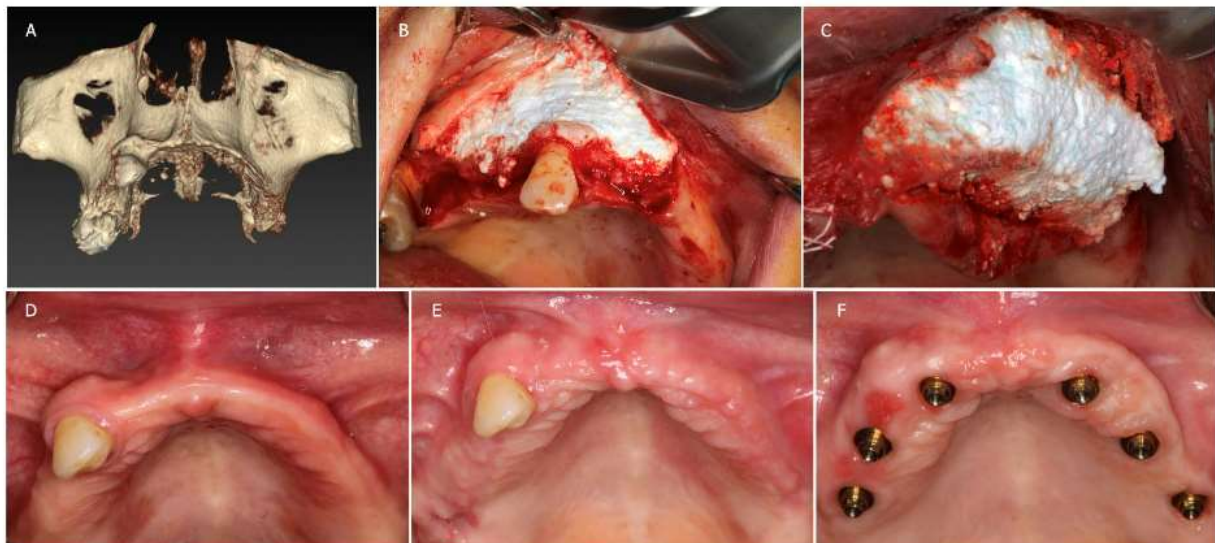


Figure 4- Total maxillary horizontal augmentation and bi-lateral sinus augmentation with delayed implant placement. A- initial CBCT demonstrating insufficient bone for implant placement, B- right side flap and BA placement, C- left side flap and BA placement, D- initial clinical presentation before treatment, E- following 3-months healing of the bone augmentation, and F- following 6-months post implant placement.

In case #5, two implants (#13 and #24) were still present, securing an old full arch ceramic bridge. Surgery involved opening three separate flaps that were interconnected using a subperiosteal tunneling technique [15]. Each flap had only a small vertical releasing

incision, extending only 3 mm past the mucogingival line. The bilateral sinus lift, horizontal augmentation, and suturing were performed in the same manner as the previous surgery. However, this patient returned home using her old bridge, secured



by only two implants. Following a 5-month healing period, one of the implant platforms fractured, necessitating an earlier implant surgery by 1-month. A continuous full arch crestal flap was created with no vertical releasing incisions, exposing only the crestal part of the bone, and the two old implants were removed. Six new implants were placed, and immediate loading was achieved with a

newly pre-made temporary hybrid prosthesis. Before suturing, and after placing the six multi-units abutments, additional BA bone cement graft was applied to enhance bone volume and stimulate soft tissue growth, augmenting soft tissue volume as well. After another 6-month osseointegration period, a final Nobel Procera hybrid prosthesis was fabricated and installed (Fig. 5).

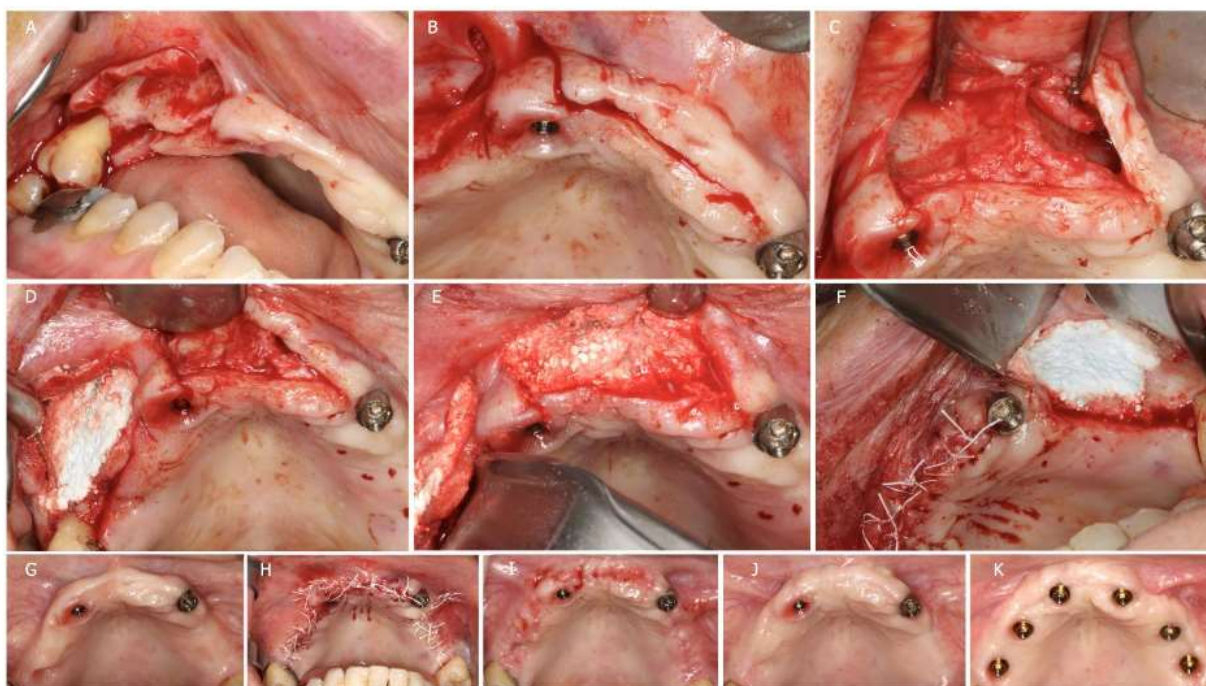


Figure 5- Maxillary horizontal augmentation and bi-lateral sinus augmentation with delayed implant placement. A- right side flap design, B- anterior flap design, C- labial view of the anterior bone defects, D- BA horizontal augmentation and right sinus augmentation, E- BA horizontal augmentation in the anterior region, F- BA horizontal augmentation and left sinus augmentation, G- initial maxillary presentation, H- flap sutured in tension after the augmentation surgery, I- removal of the sutures after 2- weeks, J- 5-months post augmentation, and K- 6-months post implant placement using guided surgery with immediate loading.

## SECOND GROUP: HORIZONTAL BONE GRAFTING WITH IMMEDIATE IMPLANT(S) PLACEMENT

In two of the cases, bone grafting and implant placement were performed immediately after tooth extraction.

In case #6, a male patient had an active infection in tooth #45 with prior Endodontic treatment present, leading to the complete

loss of the buccal plate and the presence of an active fistula. The infected tooth was extracted, and the bone site was thoroughly debrided. A small mid-crestal incision in the mesial papilla (2mm) was made without any vertical releasing incision. An immediate implant (Nobel Parallel, 3.75x15) was placed, leaving almost all the buccal implant threads exposed. A 5mm healing abutment was then

positioned over the implant. Subsequently, BA was applied and pressed like described previously. The soft tissue around the socket was sutured to achieve maximal closure, intentionally avoiding complete primary closure to prevent tissue deformation but stabilizing the soft tissue around the

abutment. A wound dressing (Augma Shield™) was trimmed and applied over the surgical site to protect the exposed bone cement. After a healing period of 5-months, a final impression was taken, and the final Procera crown was installed (Fig. 6).

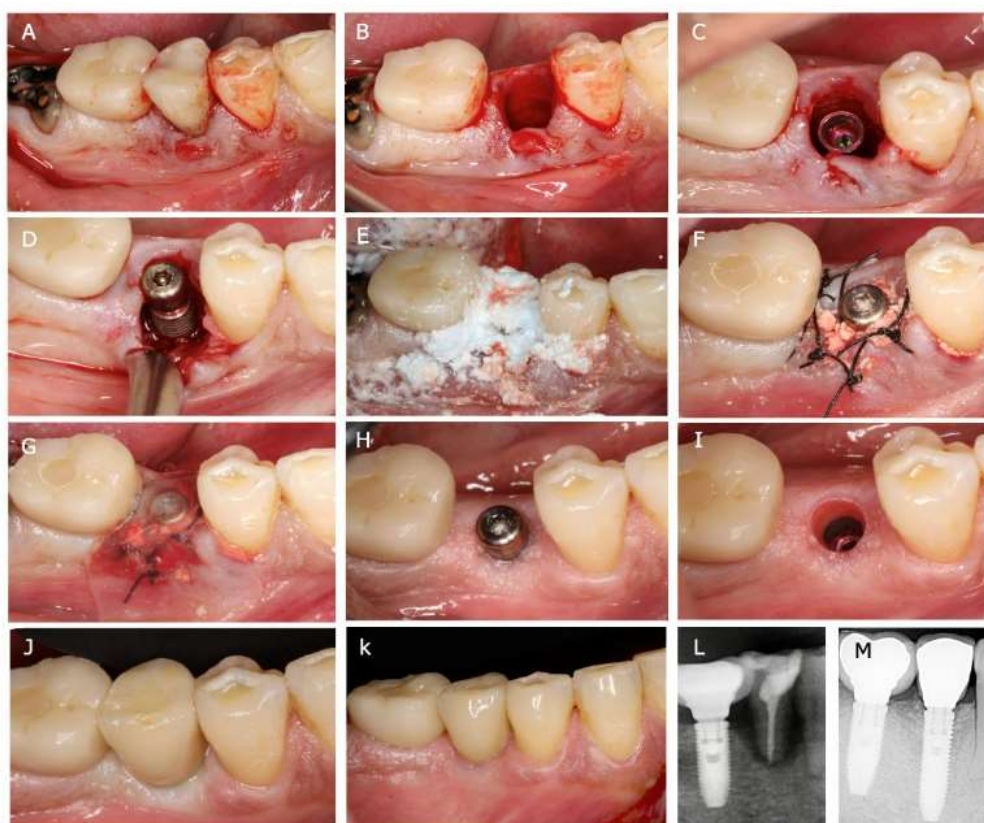


Figure 6- Immediate implant in an infected horizontal defect. A- initial clinical view, B- tooth extraction, C- implant placed, D- labial view of the buccal defect, E- BA buccal-occlusal application, F- suture placement for closure around the healing abutment, G- Augma Shield placed over the exposed BA, H and I- gingiva demonstrating a lack of inflammation after 5-months healing, J- final crown placement, K- 1.5 years post restoration, L- initial radiograph, and M- final radiograph 2-years post restoration.

The case #7, a female, presented with a cyst on tooth #22 with an active fistula, and the bony area where tooth #24 had been extracted previously had significant horizontal volume loss. A surgical flap was created extending from the mesial of tooth #25 to the distal of tooth #11, while preserving the papilla between the central incisors. Tooth

#22 was extracted, and the cyst was carefully removed. Two implants were then placed in the correct prosthetic positions, with one covered by a cover screw (#24) and the other with a 3mm healing abutment (#22). Immediately after placing BA, suture placement was performed while maintaining flap tension and in maximal closure, leaving 1

mm of cement exposed crestally. The patient used her modified old removable partial denture for 6-months to allow osseointegration and graft maturation.

Subsequently, the implants were exposed, and final Procera crowns were fabricated and installed (Fig. 7).

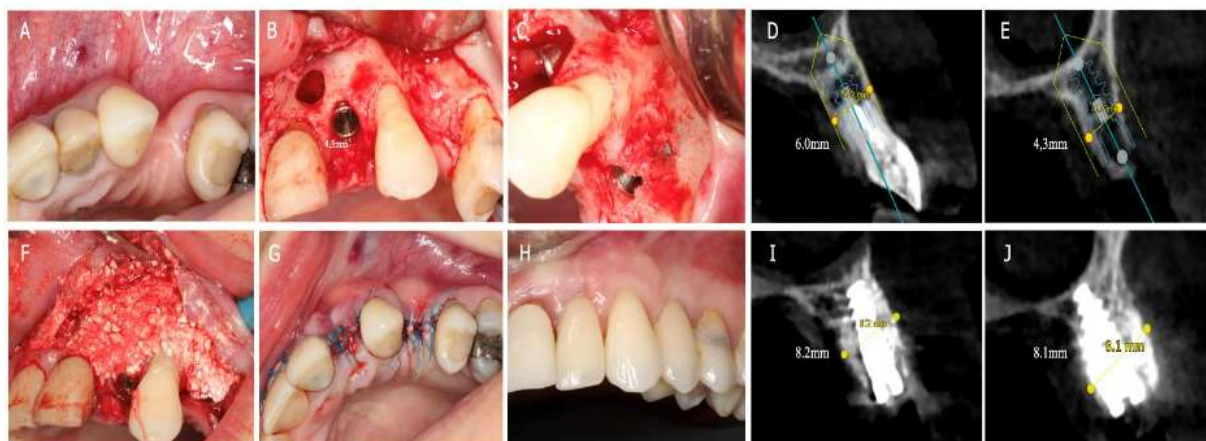


Figure 7- Horizontal augmentation with immediate implant placement. A- initial presentation, B- flap elevation and lateral incisor implant placement, C- 1<sup>st</sup> premolar implant with buccal bone fenestration, D- initial CBCT cross-section of the lateral incisor, E- initial CBCT cross-section of the 1<sup>st</sup> premolar, F- BA bone graft placed, G- flap sutured in tension with maximum closure (1mm of BA exposed), H- 5-year follow-up post restoration, I- 6-month post op CBCT cross-section of the lateral incisor, and J- 6-month post op CBCT cross-section of the 1<sup>st</sup> premolar.

Two of the cases (#8 and 9) in this surgical group involved horizontal augmentations of the quadrant with immediate implant placement but without immediate loading. Both cases followed the same protocol. A crestal surgical flap was created and elevated, encompassing the mesial papilla (and distal papilla in one case), with no vertical releasing incisions. The flap was detached from the bone 1 to 2 mm ahead of the horizontal defect. Implants were placed on the thin bony ridge in the correct prosthetic positions, with some threads exposed on the buccal aspect of the implants (between 3 and 5 mm). The implants were then had cover screws or healing abutments placed. BA graft material was applied to cover the exposed implant threads. The flap was maintained under tension during suturing, ensuring maximal closure while leaving 1 to 3 mm of bone

cement exposed crestally. The wounds were then covered with Augma Shield as a wound dressing. The patients did not receive any rehabilitation in the treated area for 6-months. After this healing period, final fixed prosthetics, Procera zirconia/ceramic bridges were fabricated and placed (Fig. 8).

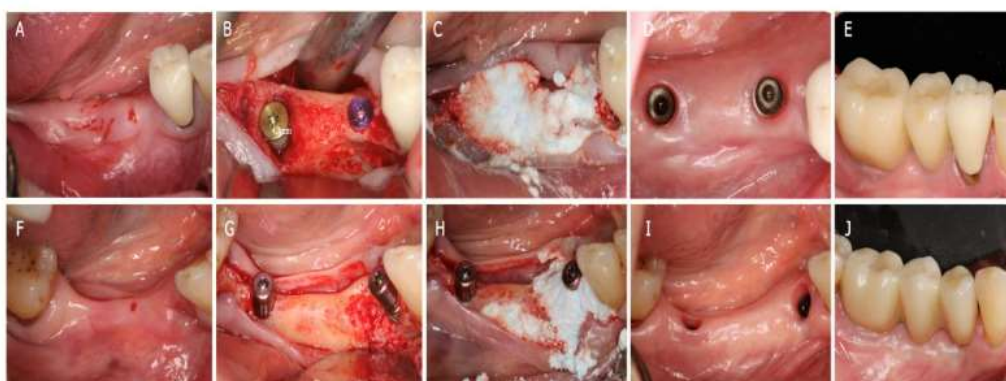


Figure 8- Horizontal augmentation with immediate implants (Cases 8 and 9). A- initial view (Case 8), B- flap reflection and implants placed, C- BA bone graft placed, D- occlusal view 6-months post-surgery demonstrating a lack of inflammation, E- 1-year post prosthetic placement, F- initial view (Case 9), G- flap reflection and implants placed, H- placement of BA bone graft, I- 6-months post-surgery, J- 1-year post placement of the final prosthesis.

Case #10 involved a re-surgery of a horizontally bone augmented site that was initially treated using the sausage technique (ST)<sup>16,17</sup>. But the first horizontal augmentation performed with ST did not fully integrate after 8 months. During the reopening procedure, all loose grafting material was meticulously removed from the site using a bone curette. After reassessment, it was decided to proceed with implant placement (3 implants) because some horizontal bone gain had occurred, albeit less than what was originally required. Following implant placement, an extensive

BA bone graft was performed to augment the insufficient bone around the implant platforms. Simultaneously, efforts were made to enhance soft tissue volume and quality, eliminating the need for mucogingival surgery following bone augmentation<sup>16</sup>. Four months later, each of the three implants was exposed using two small perpendicular incisions crestally made with a 15-blade scalpel, and healing abutments were placed. After a two-week healing period, final impressions were taken, and a three-unit Nobel Procera bridge was fabricated and installed (Fig. 9).

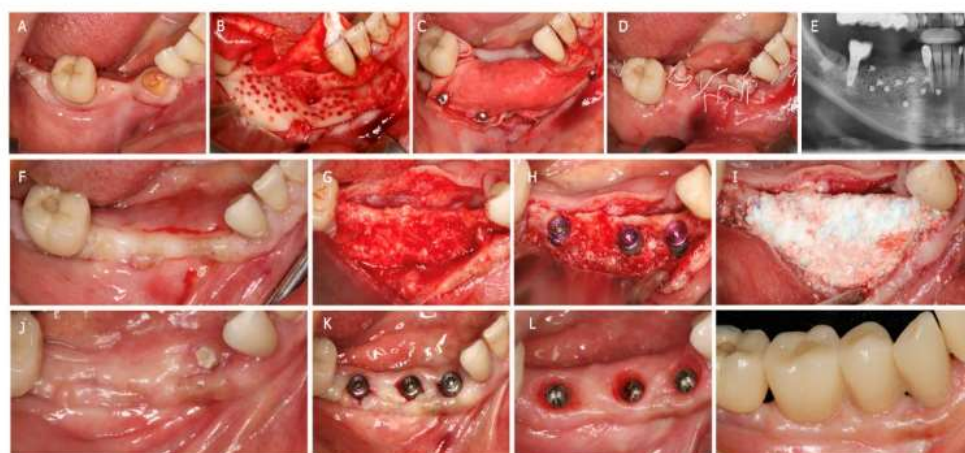


Figure 9- Horizontal augmentation with immediate implants (Case #10). A- initial clinical view, B- extensive flap elevation, root extraction and decorticalization, C- sausage technique, D- suture placement, E- post-surgery radiograph, F- occlusal view after 8-months post-surgery, G- surgical flap without vertical releasing incisions, H- implants placed, I- following BA placement, J- 4-months post BA horizontal augmentation, K- following implant exposure and healing abutment placement, L- 2-weeks post implant exposure, and M- 1-year post placement of the final prosthesis.

### THIRD GROUP: HORIZONTAL BONE GRAFTING WITH IMMEDIATE IMPLANT PLACEMENT AND IMMEDIATE LOADING, INCLUDING TEMPORARY PROSTHODONTICS

In case #11, a male patient had two teeth (#21 and #23) with an old failing natural tooth bridge, exhibiting mobility and mild suppuration. Both teeth were extracted, and two immediate implants with immediate load were placed at both sites. The procedure did not involve surgical flap reflection, and only a 3mm vertical release extending to the mucogingival line on the distal of the left upper canine socket was made. The periosteum between the 2 sockets was detached using the tunneling technique<sup>15</sup>. This technique was employed between the two sockets to fully expose the buccal bone defects. Prior to performing the bone graft, a temporary pre-made bridge was adapted to the implants with two titanium temporary

abutments. Subsequently, bone grafting was done with BA through the sockets. It was pressed using dry gauze for 3 seconds, followed by another 3 seconds with dry gauze and a surgical periosteal elevator. Only the 3mm vertical release was sutured, and any exposed cement in the sockets was covered by the temporary bridge itself, which was adapted to the soft tissue. Following a 6-month healing period, the final three-unit bridge was fabricated and placed (Fig. 10). One year later, the patient lost the lateral and the canine teeth of the maxillary right quadrant and opted for a complete maxillary rehabilitation (All-on-5). All remaining maxillary teeth were extracted, and the two implants from the previous surgery were utilized in the new rehabilitation. Upon flap elevation, the extent of bone augmentation performed in the previous surgery became clearly visible (Fig. 10-E).

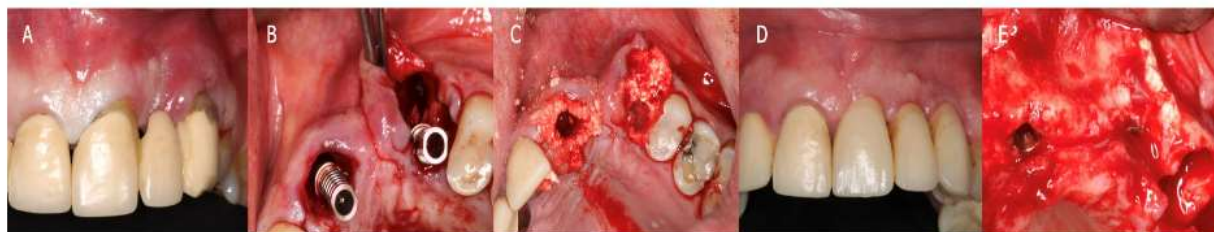

Figure 10- Horizontal augmentation with immediate implant and immediate load (case #11). A- initial clinical view, B- implants placed and absence of buccal bone at the canine noted, C- BA graft placed and removal of the healing abutments, D- 1-year post placement of the final prosthesis, and E- All-on-5 flap elevation and view of the previous graft placement at 1-year.

Case #12 involved a total mandibular rehabilitation with an All-on-4 procedure, necessitating the extraction of several teeth in poor condition and removal of three old failing implants. Particularly significant implant failure was due to peri-implantitis related bone loss on the left side of the mandible. The three implants were explanted, along with five aesthetically and functionally compromised

natural teeth. Following the extractions, a crestal full-thickness flap was elevated from first molar to first molar, extending apically to the mental nerve foramen. Following the All-on-4 protocol the bony crest was subsequently leveled and prepared for placement of four implants<sup>18;19</sup>. However, on the left premolar region, a pronounced horizontal defect existed due to peri-

implantitis involving the previously extracted implant. Despite this challenge, four implants were placed, with the left posterior implant having 8mm of its 15mm length exposed mesially and buccally. After placement of multi-units (MUA), titanium abutments were positioned over the four implants, with bone grafting being performed using BA. The flap was immediately closed and kept under tension during suturing around the MUA's. A

temporary hybrid prosthesis was adapted and immediately placed. After four months, the final hybrid Procera prosthesis was fabricated and installed. In this case, despite the need for a longer surgical flap to locate the mental nerve, no membranes, fixation screws, or pins were utilized. Additionally, as in all 14 cases presented in this study, the bone grafting process with BA bone cement took less than one minute to complete (Fig. 11).

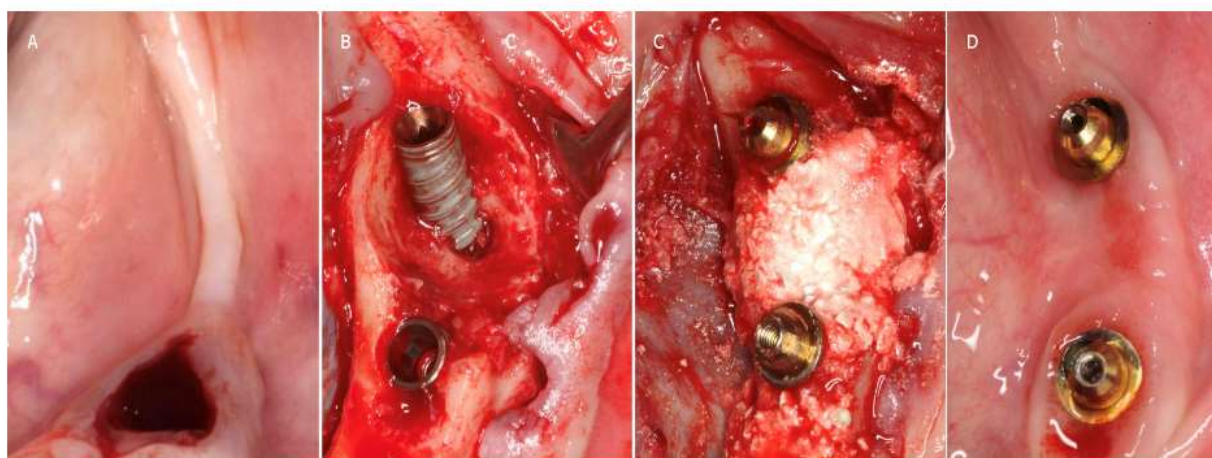


Figure 11- Mandible All-on-4 with bone horizontal augmentation on the left premolars site (case #12). A- initial clinical view after extractions of the socket at the 1<sup>st</sup> premolar, B- implants placed on the left side and the horizontal defect on the posterior implant, C- BA bone graft covering the bony defect and exposed implant threads, and D- 2.5-years post restoration after removal of the prosthesis during recall appointment.

The last two cases involved single missing teeth, one was a left central incisor, and the other was the right first premolar. Both cases presented significant horizontal bone loss.

The left central incisor (case #13) was lost due to trauma 1.5-months prior. A small crestal surgical flap was created from the mesial papilla (included) to the mesial papilla of the left lateral incisor, where a small vertical releasing incision was made, just before the papilla, approximately 1 mm across the mucogingival line. The bony defect was then exposed and carefully debrided, removing all granulation tissue and soft tissue debris. The

next step involved placing the implant in the ideal prosthetic position, resulting in an implant with thread exposure of 4 mm circumferentially and 6 mm on the buccal aspect. Before performing the BA bone cement grafting, a temporary crown was fabricated and adapted with a pre-made resin crown, composite material, and a temporary titanium abutment. Next, BA bone graft was placed, gently moving the flap away with a periosteal elevator. The bone cement was pressed for 3 to 4 seconds using dry gauze in an oblique buccal-to-palatal direction and then pressed again for an additional 4 seconds with dry gauze and a wide-tip

periosteal elevator. During BA placement, the implant platform was protected with a healing abutment, which was carefully removed after grafting and replaced with the temporary screw retained crown. Suturing was then performed with the temporary crown already in place, consisting of one suture in each of the three papillae included in the surgical flap.

The sutures were removed two weeks later, and at five months, a new more refined temporary crown in acrylic was created to develop ideal emergence profile and placed, which remained in place for two months until the final Procera crown was fabricated and installed (Fig. 12).

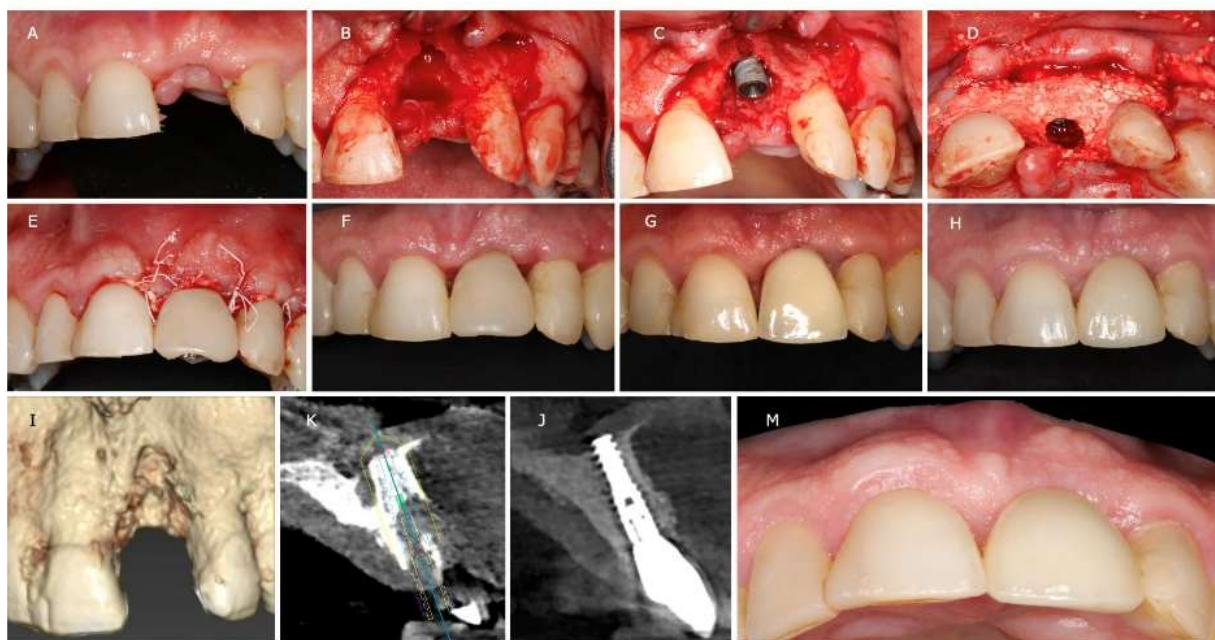


Figure 12- Implant with immediate horizontal augmentation and immediate load in the aesthetic zone (case #13). A- initial clinical view, B- surgical flap elevation noting a large horizontal bone defect, C- implant placed noting threat exposure circumferentially. D- BA bone graft placed and removal of the healing abutment, E- placement of the temporary crown and suturing of the papillae, F- 25-days post-surgery, G- second provisional crown 5-months post-surgery, H- final Procera crown 1-year post placement, I- initial CBCT buccal view, K- CBCT cross-section during surgery planning, J- CBCT cross-section 1-year of the implant/bone augmentation for evaluation, and M- view of the buccal ridge from an incisal view 1-year post-surgery.

In the premolar horizontal augmentation case (case #14), the same protocol as the previous case was followed. A small crestal surgical flap was created, including the mesial and distal papillae of the edentulous space. The implant was positioned in the optimal prosthetic location, leaving the middle portion exposed on the buccal side due to a dehiscence of the buccal ridge. After preparing the temporary crown, BA bone grafting was placed, and the

temporary crown was inserted on the implant. Suturing was performed in the same manner as the previous case, with sutures securing only the two papillae, mesial and distal to the temporary crown. After 6-months, the final Procera crown was fabricated and installed successfully for aesthetic results (Fig. 13).

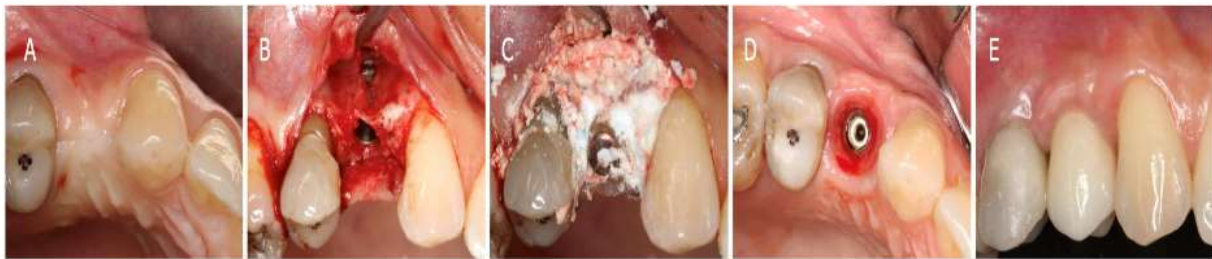

Figure 13- Implant with immediate horizontal augmentation and immediate load of the 1<sup>st</sup> premolar Case #14). A- initial clinical view, B- surgical flap was elevated following implant placement with buccal fenestration noted, C- BA bone graft was placed, D- occlusal view of the implant platform and soft tissues with a visible augmented volume at 6-months post implant placement and provisionalization, and E- buccal aspect after 1-year post restoration with the final crown.

## Results:

Utilizing a minimally invasive technique, Bond Apatite was employed in 14 clinical cases involving various types and sizes of horizontal defects, resulting in the placement of 34 implants within grafted areas. Seventeen implants were inserted 5 to 6 months following the bone graft procedure, while 17 implants were placed simultaneously with the bone graft. All cases were monitored for a follow-up period ranging from 1.5-years to 5-years. Notably, none of the implants experienced failure, and all exhibited complete coverage with bone and high-quality, robust, keratinized soft tissue lacking any evidence of inflammation, even in the absence of free gingival grafts. Visual assessments consistently revealed a significant increase in volume within the grafted areas.

Furthermore, cone beam computed tomography (CBCT) scans were performed on all patients 1-year post horizontal augmentation and imported into the DTC Studio Implant software for comparative analysis of post-operative bone volume compared to pre-surgery measurements within the same area or view. Cone beam computed tomography (Newton VG) is highly

accurate and reproducible in linear measurements in the axial and coronal image planes, and in different areas of the maxillofacial region<sup>20</sup>. It is a reliable tool for implant-planning measurements and evaluation of pre and post treatment views<sup>21</sup>. Linear measurements were conducted on the axial bucco-lingual view of planned implants (pre-surgery) and then on the same bucco-lingual axial view of placed implants (1-year post-surgery). The results indicated a mean horizontal bone gain of 5.75 mm across the various implants placed in the 14 patients, with the minimum gain measuring 1.3 mm and the maximum reaching 9.7 mm (Table 1).



Table 1- Results of bone measurements of the 14 cases in the study.

Case number	Patient Age	Patient gender	Region of measurement	3D-CT before bone	3D-CT after bone graft	Bone gain (after 1 year)
1	69	M	1 <sup>st</sup> molar of the right maxilla	2.8mm	12.5mm	+9.7mm
2	49	M	1 <sup>st</sup> molar of the left mandible	3.3mm	12.3mm	+9.0
3	54	F	Teeth 34,35 and 36	2.6mm; 5.7mm; 5.0mm	5.9mm; 6.9mm; 7.6mm	+3.3mm; +1.2mm; +2.6mm
4	58	F	Tooth 12*	4.6mm	9.0mm	+4.4mm
5	64	F	Tooth 22*	6.6mm	8.5mm	+1.9mm
6	50	M	Tooth 45	3.4mm	9.8mm	+6.4mm
7	36	F	Teeth 22 and 24	6.0mm; 4.3mm	8.2mm; 8.1mm	+2.2mm; +3.8mm
8	68	F	Teeth 45 and 46	5.7mm; 8.7mm	8.0mm; 10.5mm	+2.3mm; +1.8mm
9	74	F	Teeth 44 and 46	5.8mm; 6.1mm	7.1mm; 7.8mm	+1.3mm; +1.6mm
10	55	F	Teeth 44,45 and 46	3.3mm; 5.5mm; 4.4mm	6.2mm; 10mm; 10.7mm	+2.9mm; +4.5mm; +6.3mm
11	54	M	Tooth 23	4.1mm	10.5mm	+6.4mm
12	82	F	Tooth 35	1.4mm	9.3mm	+7.9mm
13	46	M	Tooth 21	3.0mm	9.9mm	+6.9mm
14	43	F	Tooth 14	4.1mm	6.2mm	+2.1mm

\*in the 4th and 5th cases, the measurement taken was the one with less initial bone volume.

## Discussion:

Grafting of large or complex-shaped bony defects remains a challenge for dental surgeons. However, it is often necessary that oral rehabilitation through dental implants is required<sup>22</sup>. For prosthetic-driven dental implant therapy, reconstructing alveolar bone through various regenerative surgical procedures has become a predictable approach<sup>23</sup>. In cases of extensive horizontal bone resorption, augmenting bone volume before or during implant placement is essential for successful dental rehabilitation and maximizing implant survival and success<sup>24</sup>.

Several surgical approaches can be used for this augmentation, such as bone-block grafting with screw fixation, lateral augmentation using particulate bone and membrane placement for coverage, horizontal bone width gain through surgical splitting of the alveolar ridge<sup>24</sup>, or the subperiosteal bone graft tunnelling technique<sup>15</sup>. Some authors still consider autologous bone blocks the most reliable and secure procedure due to their biological properties<sup>26,27</sup>. However, issues like donor site morbidity, prolonged surgery time, and unpredictable resorption dynamics have led

to the introduction of various allografts, xenografts, and synthetic materials, many of which are commercially available<sup>25</sup>.

A randomized controlled trial by Machtei in 2018 compared hard tissue changes following socket preservation using Bond Apatite, bovine-derived xenograft (BDX), or no grafting (control). The results indicated that BA could be the material of choice for socket preservation, with a significantly higher percentage of new bone formation compared to BDX<sup>14</sup>.

Another study by Dr. Amos Yahav on different clinical applications of BA, including lateral ridge augmentation, showed similar histological results and good clinical outcomes<sup>11</sup>. These findings align with those of an experimental study in rabbits by Turri and Dahlin, which compared bone healing dynamics with calcium sulfate and deproteinized bovine bone<sup>28</sup>. They reported that the calcium sulfate group demonstrated significantly more bone regeneration at all healing periods compared to the bovine bone group.

In a clinical and histological study involving humans, ridge preservation treatment with an allograft in an experimental putty carrier plus a calcium sulfate barrier was compared to a bovine-derived xenograft (BDX) with a collagen membrane. The study concluded that the allograft mixed with calcium sulfate produced significantly more vital bone fill than the use of a xenograft with no carrier material<sup>29</sup>.

Regarding the behavior of bone tissue in the presence of calcium sulfate, Walsh and colleagues used immunohistochemical techniques to identify various growth factors in spongy femoral defects filled with calcium sulfate balls<sup>30,31</sup>. They found a higher

concentration of bone morphogenic proteins (BMP-2 and BMP-7), transforming growth factor-beta (TGF- $\beta$ ), and platelet-derived growth factor (PDGF) in the presence of calcium sulfate. These factors play crucial roles in connective tissue regeneration and new bone formation, suggesting that calcium sulfate not only acts as a filler but also has an active role in osteogenesis. Additionally, biocompatibility studies have shown that calcium sulfate is well-tolerated by the body. In an *in vitro* gingival fibroblast cultivation study, Payne and colleagues found that calcium sulfate substrates facilitated cell attachment and spreading<sup>32</sup>. Thus making it suitable for guided tissue regeneration in surgical sites where primary wound closure cannot be achieved, unlike other barrier materials like ePTFE membranes and PLLA membranes.

The fact that tension-free flaps are not required, nor primary soft tissue closure at the time of suturing, also contributes to reduced post-surgical swelling, bleeding, and potential pain for the patient. It also eliminates the influence of muscle tension on the flap. Augma Bond Apatite has proven to be a predictable material for bone augmentation, even in cases of substantial large bony defects, allowing for the simultaneous placement of implants during graft placement, with or without immediate loading.

This material not only serves as a filler but also appears to play a bioactive role in the grafted site, promoting angiogenesis and osteogenesis during the formation of new bone, while simultaneously enabling fast soft tissue proliferation across its surface. Its bacteriostatic nature eliminates the risk of contamination when left exposed. Another significant aspect is its complete absorption

and replacement by bone over time. Its ability to act as both a scaffold tenting the area and a filler with its cementing properties makes graft placement and stabilization faster and easier, eliminating the need for additional barriers. These virtues enhance and shorten the healing time in a predictable manner, which is essential for the rapid and high-quality formation of new bone, reducing the waiting time between graft placement and implant placement when a delayed surgical approach is indicated. It also enables faster rehabilitation and recovery for the patient.

Overall, these studies support the use of Bond Apatite and calcium sulfate in various regenerative and implant-related procedures, highlighting their efficacy and biocompatibility in promoting bone regeneration and soft tissue healing.

## Conclusion:

The data presented in this study, along with findings from other studies and reports, provide a strong foundation for the use of Augma Bond Apatite in the reconstruction of various bony defects, including horizontal bone augmentation. This material has demonstrated its effectiveness not only as a scaffold and bone volume preserver but also as a reliable choice for true bone regeneration. Additionally, it significantly reduces surgical time and eliminates the need for extensive surgical flaps, membranes, or fixation pins/screws lowering treatment cost. This enables a minimally invasive bone reconstruction approach with reduced morbidity for the patient and less stress for the clinician.

Regarding soft tissue, this study aligns with previous research indicating a higher

proliferation of gingival fibroblasts in the presence of calcium sulfate. All 14 cases in this study demonstrated excellent quality and quantity of keratinized tissue around the placed implants, even without the need for additional soft tissue grafts.

In conclusion, this study demonstrates that the preparation and use of Augma Bond Apatite is a straightforward, cost-effective, and efficient reconstructive treatment that can be successfully performed for horizontal bone augmentation, even by less experienced clinicians. However, further studies are needed to explore this material and its clinical applications in more detail.



**Conflict of Interest Statement:**

None

**Funding Statement:**

None

**Acknowledgement Statement:**

None

## References:

- Jensen AT, Jensen SS, Worsaae N. Complications related to bone augmentation procedures of localized defects in the alveolar ridge. A retrospective clinical study. *Oral Maxillofac Surg.* 2016 Jun; 20(2):115-22. doi: 10.1007/s10006-016-0551-8. Epub 2016 Mar 2. PMID: 26932593.
- Iancu SA, Referendaru D, Iancu IA, Bechir A, Barbu HM. Immediate postoperative complications after lateral ridge augmentation - a clinical comparison between bone shell technique and sticky bone. *J Med Life.* 2022 Apr; 15(4):533-538. doi: 10.25122/jml-2021-0347. PMID: 35646177; PMCID: PMC9126457.
- Jensen AT, Jensen SS, Worsaae N. Complications related to bone augmentation procedures of localized defects in the alveolar ridge. A retrospective clinical study. *Oral Maxillofac Surg.* 2016 Jun; 20(2):115-22. doi: 10.1007/s10006-016-0551-8. Epub 2016 Mar 2. PMID: 26932593.
- McAllister BS, Haghghat K. Bone augmentation techniques. *J Periodontol.* 2007 Mar; 78(3):377-96. doi: 10.1902/jop.2007.060048. PMID: 17335361.
- Baranes D, Kurtzman GM. Biphasic Calcium Sulfate as an Alternative Grafting Material in Various Dental Applications. *J Oral Implantol.* 2019 Jun; 45(3):247-255. doi: 10.1563/aaid-joi-D-18-00306. Epub 2019 May 1. PMID: 31042446.
- Dreesman H. Über Knochenplombierung. *Beitr Klin Chir.* 1892; 9: 804-810.
- Lillo R, Peltier LF. The substitution of plaster of Paris rods for portions of the diaphysis of the radius in dogs. *Surg Forum.* 1956; 6:556-8. PMID: 13391548.
- López J1, Alarcón M2, Sulfato de calcio: propiedades y aplicaciones clínicas. *Rev. Clin. Periodoncia Implantol. Rehabil. Oral Vol.* 4(3); 138-143, 2011.
- Payne JM, Cobb CM, Rapley JW, Killoy WJ, Spencer P. Migration of human gingival fibroblasts over guided tissue regeneration barrier materials. *J Periodontol.* 1996 Mar; 67(3):236-44. doi: 10.1902/jop.1996.67. 3. 236. PMID: 8708955.
- Torrejon-Moya, A.; Apalimova, A.; González-Navarro, B.; Zaera-Le Gal, R.; Mari-Roig, A.; López-López, J. Calcium Sulfate in Implantology (Biphasic Calcium Sulfate/Hydroxyapatite, BCS/HA, Bond Apatite®): Review of the Literature and Case Reports. *Coatings* 2022,12,1350. <https://doi.org/10.3390/coatings12091350>
- Yahav A, Kurtzman GM, Katzap M, Dudek D, Baranes D. Bone Regeneration: Properties and Clinical Applications of Biphasic Calcium Sulfate. *Dent Clin North Am.* 2020 Apr; 64(2):453-472. doi: 10.1016/j.cden.2019.12.006. Epub 2020 Jan 18. PMID: 32111280.
- Dudeck D, Warmusz O, Reichman-Warmusz E, Kurtzman GM. Treatment of an ossifying fibroma of the mandible with endodontic microsurgery and grafting with a biphasic calcium sulfate material: a case report. *Ann Med Surg (Lond).* 2023 Jul 15; 85(8):4167-4173. doi: 10.1097/MS9.0000000000001068. PMID: 37554914; PMCID: PMC10406028.
- Katzap M, Kurtzman GM. Utilization of Biphasic Calcium Sulfate as Socket Preservation Grafting as a Prelude to Implant Placement: A Case Report. *J Oral Implantol.* 2022 Oct 1; 48(5):412-418. doi: 10.1563/aaid-joi-D-21-00010. PMID: 34091688.

14. Machtei EE, Mayer Y, Horwitz J, Zigdon-Giladi H. Prospective randomized controlled clinical trial to compare hard tissue changes following socket preservation using alloplasts, xenografts vs no grafting: Clinical and histological findings. *Clin Implant Dent Relat Res.* 2019 Feb; 21(1):14-20. doi: 10.1111/cid.12707. Epub 2018 Dec 28. PMID: 30592368.
15. Kim HS, Kim YK, Yun PY. Minimal invasive horizontal ridge augmentation using subperiosteal tunneling technique. *Maxillofac Plast Reconstr Surg.* 2016 Nov 5; 38(1):41. doi: 10.1186/s40902-016-0087-8. PMID: 27882310; PMCID: PMC5097073.
16. Urban I. Vertical and horizontal ridge augmentation: new perspectives. 1st ed. Germany: Quintessence Publishing 2017. p. 117-46.
17. Urban IA, Nagursky H, Lozada JL. Horizontal ridge augmentation with a resorbable membrane and particulated autogenous bone with or without anorganic bovine bone-derived mineral: a prospective case series in 22 patients. *Int J Oral Maxillofac Implants.* 2011 Mar-Apr; 26(2):404-14. PMID: 21483894.
18. Maló P, Rangert B, Nobre M. "All-on-Four" immediate-function concept with Brånemark System implants for completely edentulous mandibles: a retrospective clinical study. *Clin Implant Dent Relat Res.* 2003;5 Suppl 1:2-9. doi: 10.1111/j.1708-8208.2003.tb00010.x. PMID: 12691645.
19. Taruna M, Chittaranjan B, Sudheer N, Tella S, Abusaad M. Prosthodontic perspective to all-on-4® concept for dental implants. *J Clin Diagn Res.* 2014 Oct;8(10):ZE16-9. doi: 10.7860/JCDR/2014/9648.5020. Epub 2014 Oct 20. PMID: 25478475; PMCID: PMC4253293.
20. Moshfeghi M, Tavakoli MA, Hosseini ET, Hosseini AT, Hosseini IT. Analysis of linear measurement accuracy obtained by cone beam computed tomography (CBCT-NewTom VG). *Dent Res J (Isfahan).* 2012 Dec; 9(Suppl 1):S57-62. PMID: 23814563; PMCID: PMC3692201.
21. Suomalainen A, Vehmas T, Kortensniemi M, Robinson S, Peltola J. Accuracy of linear measurements using dental cone beam and conventional multislice computed tomography. *Dentomaxillofac Radiol.* 2008 Jan; 37(1):10-7. doi: 10.1259/dmfr/14140281. PMID: 18195249.
22. Schulz MC, Holtzhausen S, Nies B, Heinemann S, Muallah D, Kroschwald L, Paetzold-Byhain K, Lauer G, Sembdner P. Three-Dimensional Plotted Calcium Phosphate Scaffolds for Bone Defect Augmentation-A New Method for Regeneration. *J Pers Med.* 2023 Mar 2; 13(3):464. doi: 10.3390/jpm13030464. PMID: 36983646; PMCID: PMC10058839.
23. McAllister BS, Haghghat K. Bone augmentation techniques. *J Periodontol.* 2007 Mar; 78(3):377-96. doi: 10.1902/jop.2007.060048. PMID: 17335361.
24. Smeets R, Matthies L, Windisch P, Gosau M, Jung R, Brodala N, Stefanini M, Kleinheinz J, Payer M, Henningsen A, Al-Nawas B, Knipfer C. Horizontal augmentation techniques in the mandible: a systematic review. *Int J Implant Dent.* 2022 May 9; 8(1):23. doi: 10.1186/s40729-022-00421-7. PMID: 35532820; PMCID: PMC9086020.
25. Sanz-Sánchez I, Ortiz-Vigón A, Sanz-Martín I, Figuero E, Sanz M. Effectiveness of Lateral Bone Augmentation on the Alveolar Crest Dimension: A Systematic Review and Meta-analysis. *J Dent Res.* 2015 Sep; 94(9

- Suppl):128S-42S. doi: 10.1177/0022034515594780. doi: 10.1097/01.blo.0000030062.92399.6a.  
Epub 2015 Jul 27. PMID: 26215467. PMID: 12579023.
26. Pereira E, Messias A, Dias R, Judas F, Salvoni A, Guerra F. Horizontal Resorption of Fresh-Frozen Corticocancellous Bone Blocks in the Reconstruction of the Atrophic Maxilla at 5 Months. *Clin Implant Dent Relat Res*. 2015 Oct; 17 Suppl 2(Suppl 2):e444-58. doi: 10.1111/cid.12268. Epub 2014 Oct 27. PMID: 25346211; PMCID: PMC4616242.
27. Spin-Neto R, Stavropoulos A, Dias Pereira LA, Marcantonio E Jr, Wenzel A. Fate of autologous and fresh-frozen allogeneic block bone grafts used for ridge augmentation. A CBCT-based analysis. *Clin Oral Implants Res*. 2013 Feb; 24(2):167-73. doi: 10.1111/j.1600-0501.2011.02324.x. Epub 2011 Oct 21. PMID: 22093001.
28. Turri A, Dahlin C. Comparative maxillary bone-defect healing by calcium-sulphate or deproteinized bovine bone particles and extra cellular matrix membranes in a guided bone regeneration setting: an experimental study in rabbits. *Clin Oral Implants Res*. 2015 May; 26(5):501-6. doi: 10.1111/clr.12425. Epub 2014 Jun 21. PMID: 24954120.
29. Vance GS, Greenwell H, Miller RL, Hill M, Johnston H, Scheetz JP. Comparison of an allograft in an experimental putty carrier and a bovine-derived xenograft used in ridge preservation: a clinical and histologic study in humans. *Int J Oral Maxillofac Implants*. 2004 Jul-Aug; 19(4):491-7. PMID: 15346745.
30. Walsh WR, Morberg P, Yu Y, Yang JL, Haggard W, Sheath PC, Svehla M, Bruce WJ. Response of a calcium sulfate bone graft substitute in a confined cancellous defect. *Clin Orthop Relat Res*. 2003 Jan;(406):228-36.
31. Lazáry A, Balla B, Kósa JP, Bácsi K, Nagy Z, Takács I, Varga PP, Speer G, Lakatos P. Effect of gypsum on proliferation and differentiation of MC3T3-E1 mouse osteoblastic cells. *Biomaterials*. 2007 Jan; 28(3):393-9. doi: 10.1016/j.biomaterials.2006.09.002. Epub 2006 Sep 25. PMID: 16997372.
32. Payne JM, Cobb CM, Rapley JW, Killoy WJ, Spencer P. Migration of human gingival fibroblasts over guided tissue regeneration barrier materials. *J Periodontol*. 1996 Mar; 67(3):236-44. doi: 10.1902/jop.1996.67.3.236. PMID: 8708955.